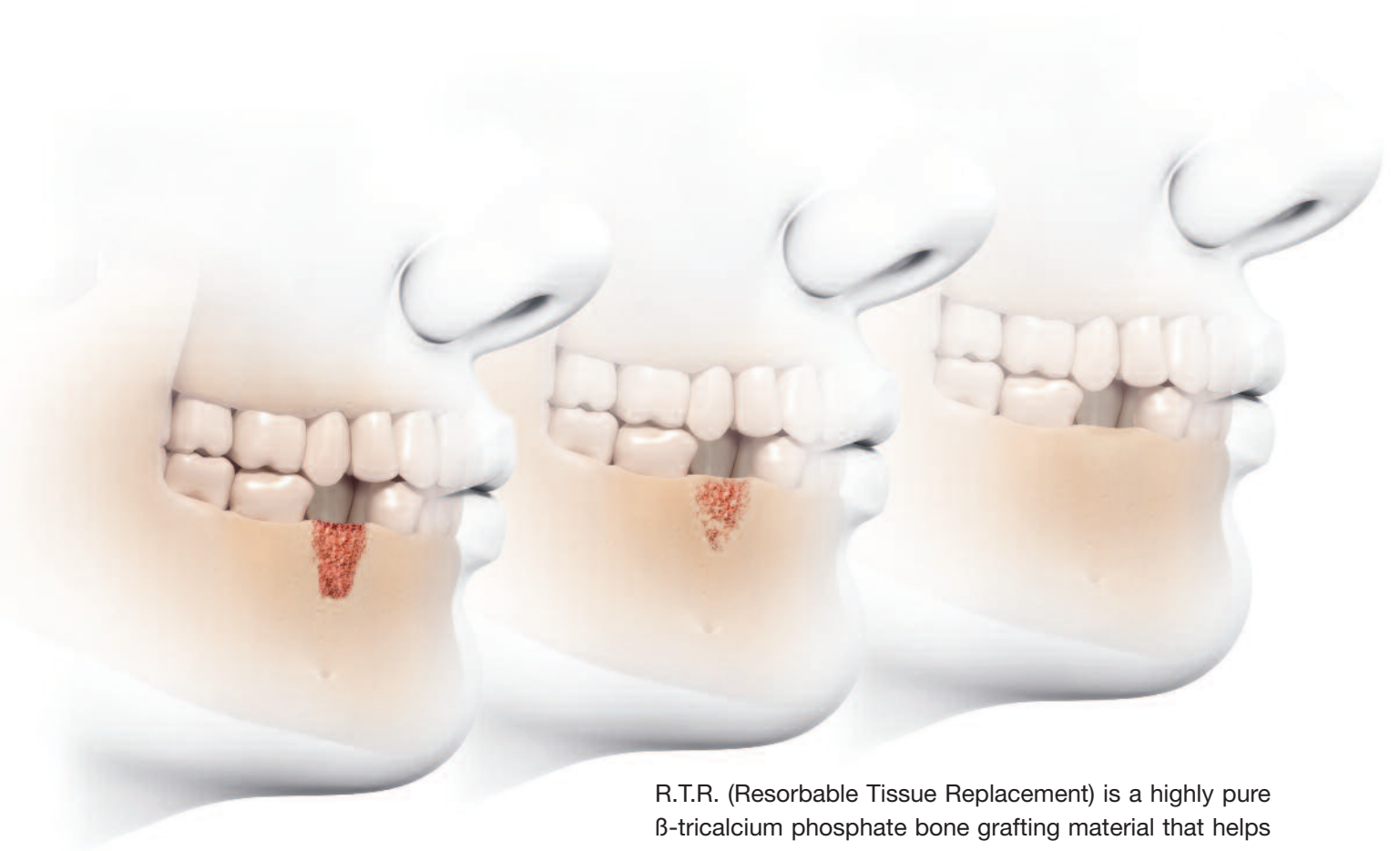



R.T.R. (Resorbable Tissue Replacement) is a highly pure  $\beta$ -tricalcium phosphate bone grafting material that helps to safely create new bone formation following an extraction or any bone loss (intrabony defect, sinus-lift...).

- **Resorbs progressively and fully:** R.T.R. releases calcium and phosphate ions helping to promote strong new bone formation.
- **Regenerates natural bone growth.** Osteoconductive micro and macroporous structures foster dense new bone growth.
- **Restores volume:** R.T.R. renews the bone integrity within 3-6 months.
- **Available in 3 presentations** (Cone, Syringe, Granules) to suit all clinical situations.

Improve your patients' extraction therapy and bone loss repair to promote future implant success with R.T.R.


## Product Presentation



**R.T.R. Cone**

Box of 2 cones each containing 0.3 cm<sup>3</sup> (Ø 6 mm, H 10 mm) of  $\beta$ -tricalcium phosphate granules + collagen\* in sterile individual packaging.

\*bovine origin



**R.T.R. Syringe**

0.8 cm<sup>3</sup> of  $\beta$ -tricalcium phosphate granules (Ø 0.5 to 1 mm) in sterile syringe, individually packaged.



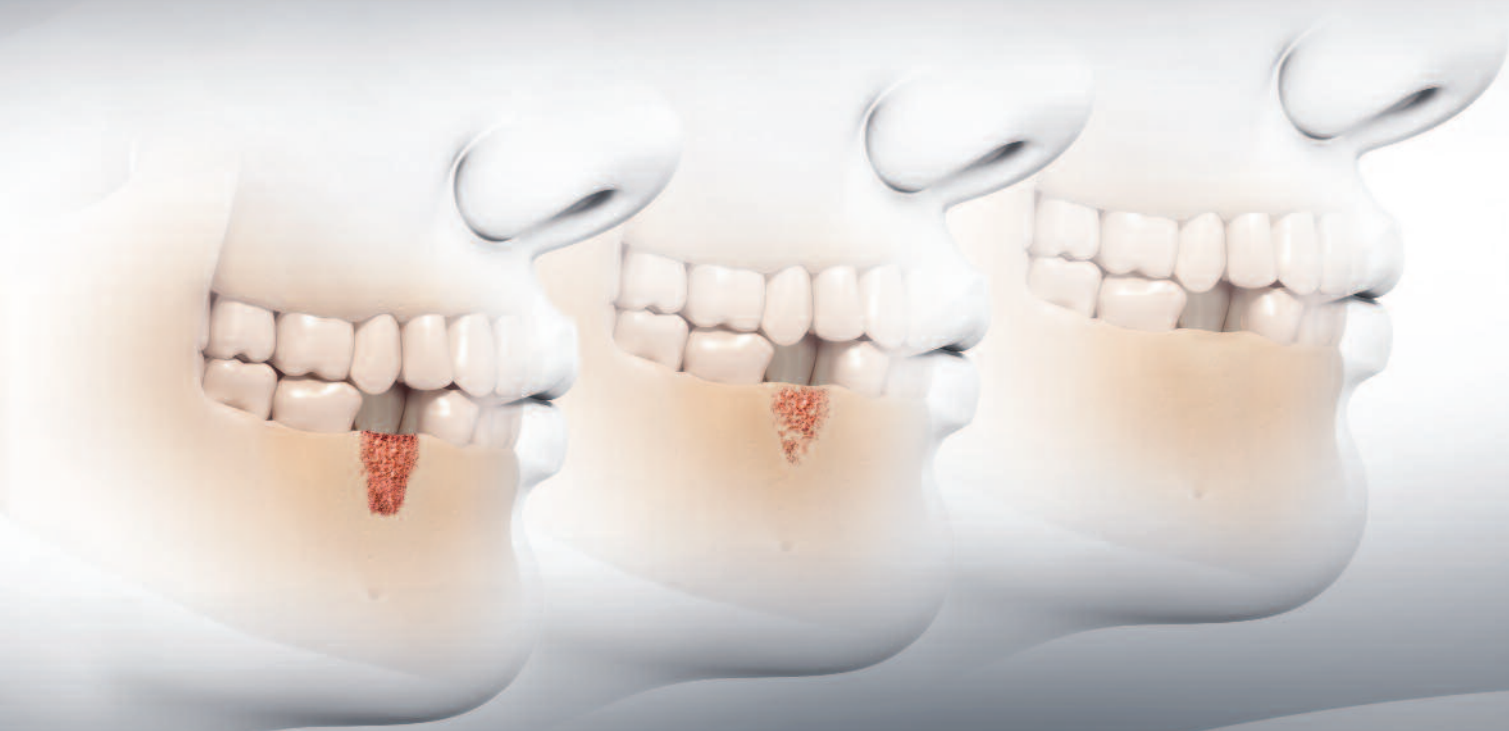**R.T.R. Granules**

Box of 1 bottle containing 2 cm<sup>3</sup> of  $\beta$ -tricalcium phosphate granules (Ø 0.5 to 1 mm) in sterile single-unit package.



The Dental Pharmaceutical Company

INNOVATIVE, SAFE AND EFFECTIVE SOLUTIONS FOR DENTISTRY WORLDWIDE



# R.T.R.

Full resorption... strong new bone formation

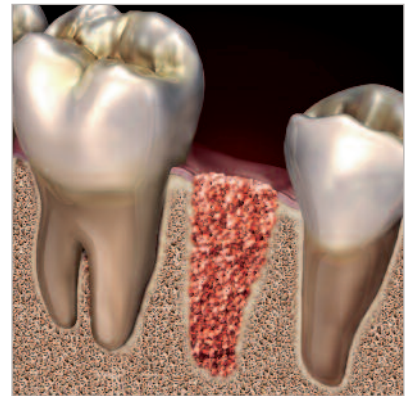


# R.T.R. – Beauty That’s Bone Deep

## R.T.R. – Fills A Void In Bone Grafting

R.T.R. gives you a safe and easy-to-use solution for both simple and complex bone augmentation therapies and helps to maintain long-term function, health and esthetics of dentition and the supportive bone structure.

R.T.R. is a synthetic bone substitute which is extremely hydrophilic, so it is drawn into the surgical site and can be easily contoured to fill any bony void. This makes R.T.R. particularly appropriate for the treatment of periodontal defects, ridge augmentations, and extraction socket therapy (post-extraction ridge preservation).

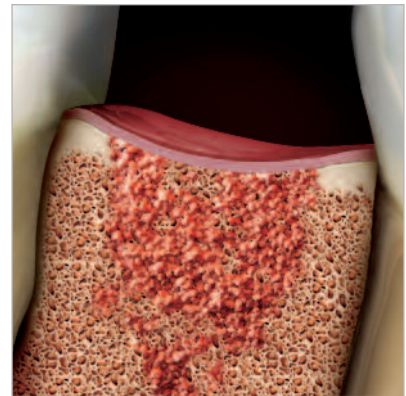


▲ Extraction site filled with R.T.R.

## R.T.R. – Pure And Purely Ingenious

R.T.R. is a biocompatible synthetic material with a high level of purity.

R.T.R. granules have a  $\beta$ -tricalcium phosphate crystalline ( $\beta$ -TCP) structure and are tested many times during the manufacturing process (X-rays, infra-red spectroscopy) to ensure the highest level of purity ( $\beta$ -TCP > 99%).  $\beta$ -TCP is well documented for its biocompatibility in dental and orthopedic treatment and causes no local or systemic toxicity.



▲ Bone regeneration with R.T.R.

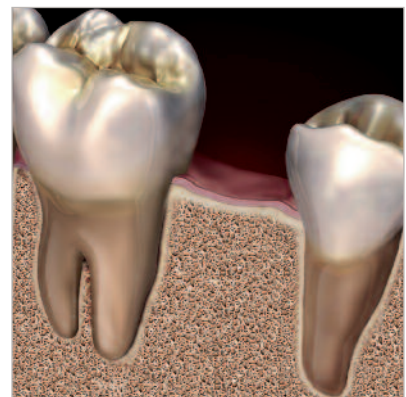## R.T.R. – Rebuilding A Solid Foundation

R.T.R. porous granules provide an optimal osteo-conductive environment that promotes the growth of new dense bone.

R.T.R. granules are both micro and macroporous. These microcavities, when impregnated with the patient's blood, promote an in-depth colonization of the substitute by osteogenic cells with new bone formation becoming biologically fixed.

R.T.R. resorbs progressively and fully.

Unlike hydroxyapatite, R.T.R. gradually releases calcium and phosphate ions to promote strong new bone formation. Within 3 to 6 months, depending on the patient physiology, R.T.R. is replaced by newly formed dense bone capable of supporting future implants.



▲ Successful new bone growth through full R.T.R. resorption.



## R.T.R. – Technical Specifications

### Properties:

R.T.R. features specific structural properties that foster osteogenic cell colonization.


**COMPOSITION:** Synthetic  $\beta$ -tricalcium phosphate granules ( $\beta$ -TCP)

**PARTICLE SIZE:** From 500  $\mu\text{m}$  to 1 mm

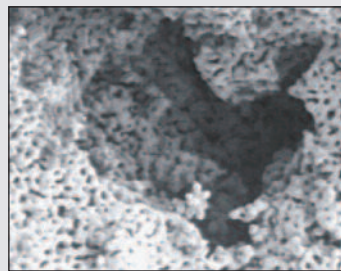
**MACROPORES:** From 100  $\mu\text{m}$  to 400  $\mu\text{m}$

**MICROPORES:** < 10  $\mu\text{m}$

**RESORPTION:** 3 to 6 months (depending on the patient's physiology)



▲ R.T.R. granule magnification of macroporous structure (x135)



▲ R.T.R. granule magnification of macroporous and microporous structure (x1000)

### Indications:

R.T.R. is indicated in most clinical cases requiring oral bone replacement:

- Post extraction socket grafting (post-extraction ridge preservation)
- Ridge augmentations
- Periodontal defects
- Peri-implant defects
- Sinus lift
- Defects following apical endodontic surgery

### Characteristics:

Features	Benefits
Synthetic $\beta$ -TCP granules	Resorbable with new bone formation
Micro and macroporous	Maximises alloplast colonization by osteogenic cells for bone augmentation
Hydrophilic material	Drawn into the surgical site and provides easy contouring when filling bony voids
High level of purity + sterilization	Biocompatibility and safety
Available in 3 presentations	Suits main clinical indications
R.T.R. Cone: addition of highly purified collagen*	Haemostatic healing and stays in place
R.T.R. Curved Syringe 0.8 cm <sup>3</sup>	Easy direct placement thanks to a simple aspiration of patient's blood or physiological solution
R.T.R. Granules 2 cm <sup>3</sup>	High volume adapted for large defects
Double sterile packaging	Meets the asepsis standards required in implantology

\* bovine origin

## R.T.R. – Clinical Applications

### case 1 Post extraction socket grafting

Tooth extraction leads to alveolar bone loss during the first months of natural healing, with an average loss of 2 to 3 mm in the maxilla and 4 to 6 mm in the mandible. The formation of alveolar clot is essential to fill this cavity.

The R.T.R. cone is carefully placed at the entry to the socket, without trying to enter the socket, to soak up the blood.

The initially dry and rigid consistency of R.T.R. changes into a cohesive and malleable gel in contact with blood.

### case 2 Periodontal defect

Treatment of an intrabony defect must be part of a global therapy. Initial nonsurgical treatment including scaling, root planing, and oral hygiene is essential to identify cases in which surgical treatment of the defect (larger than 6 mm with bleeding on probing) is indicated. After careful removal of granulation tissue and root planing, a two or three wall defect is filled with R.T.R. without the use of a membrane. Within a few months, bone repair with a long junctional epithelium is complete. The long-term success of the intrabony defect repair involves maintenance treatment.

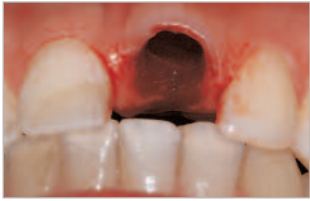### case 3 Peri-implant defect

This classic development of a vestibular space following implant insertion is easily treatable. R.T.R. prevents soft tissue invagination and ensures good osteo-integration.

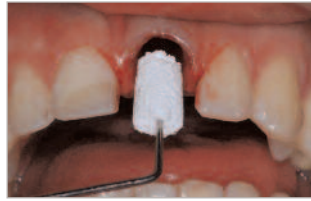
### case 4 Sinus lift

Alone or in combination with autologous bone,  $\beta$ -TCP provides an advantageous and recognized alternative to surgical protocols requiring the harvesting of a bone graft.

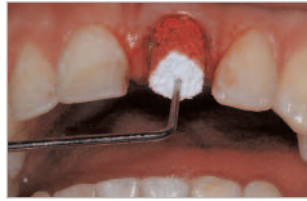R.T.R. ensures reproducible clinical results. The curved syringe delivery system is particularly useful for this technique.



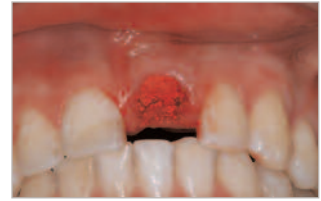
Avulsion of 21.



Application of the R.T.R. cone.

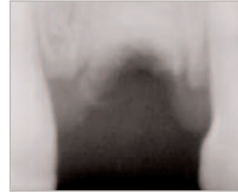


The cone is impregnated with blood.

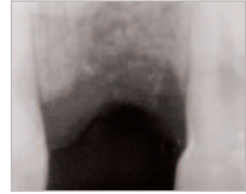


R.T.R. in place.

This consistency associated with the haemostatic action of R.T.R. ensures a perfect fit regardless of the shape of the socket. The cone must be thoroughly impregnated with blood to avoid dissociation of  $\beta$ -TCP particles during packing. Follow-up x-rays at 1 and 3 months confirm maintenance of the alveolar margins. An implant is inserted after 4 and a half months.

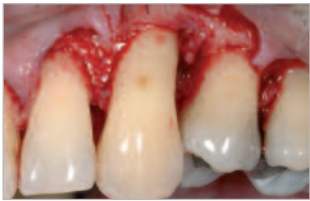

R.T.R. in place.

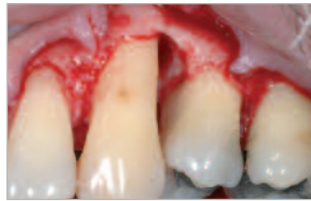

2 months postoperatively.

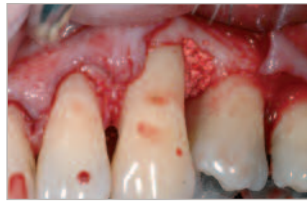Case courtesy of Dr. François Cariou  
Hospital Practice, Reims, France



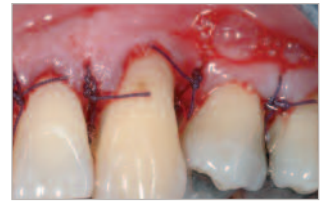
A full thickness flap is detached.



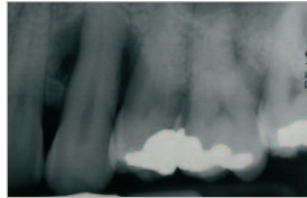
The intrabony defect is thoroughly degranulated.



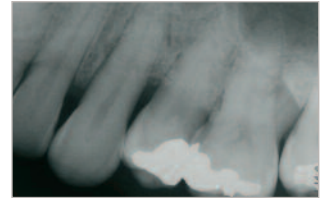
The blood/R.T.R. mixture is placed in the defect.



Vestibular view of surgical site with placed sutures.

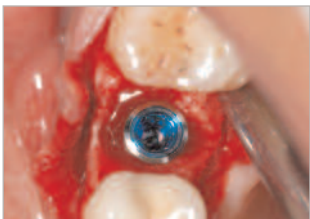

Preoperative x-ray.

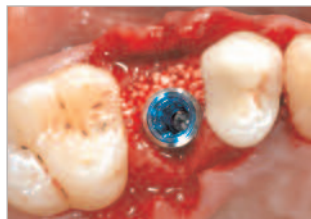

Postoperative x-ray, 6 months post surgery.

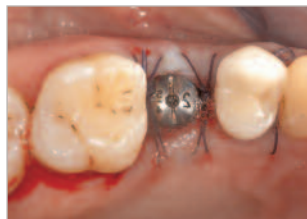Case courtesy of Dr. Charles Micheau  
Paris Diderot University, UFR of Odontology.



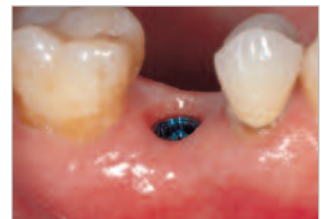Presence of vestibular space.



Application of R.T.R.

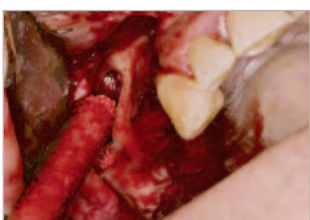

Surgical site with sutures placed.

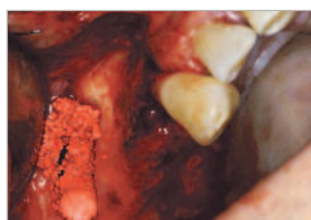


Perfect integration of implant, 3 months post surgery

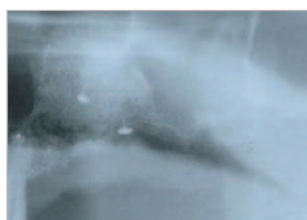
Case courtesy of Dr. Charles Micheau  
Paris Diderot University, UFR of Odontology.



Application of R.T.R.



R.T.R. in place.



Postoperative x-ray.



Histology 7 months post surgery.

Case courtesy of Dr. Thomas Lux  
Private Practice, Mannheim, Germany.