

Septodont Case Studies Collection

No. 07 - March 2014

Focus on:

R.T.R.

BIOMATERIALS FOR BONE REGENERATION
M. LABANCA

R.T.R.

β -TCP IN POST-EXTRACTION SOCKETS
O. H. ARRIBASPLATA LOCONI

BIODENTINE™

DEEP CARIOUS LESION RESTORATION
S. BANERJI

BIODENTINE™

PULP CHAMBER PERFORATION REPAIR
I. LORENZO



Editorial



Since its foundation Septodont has developed, manufactured and distributed a wide range of high quality products for dental professionals.

Septodont recently innovated in the field of gingival preparation, composites and dentine care with the introduction of Racegel, the N'Durance® line and Biodentine™, which are appreciated by clinicians around the globe.

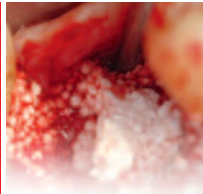


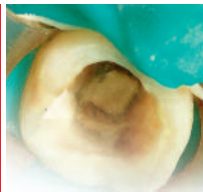
Septodont created the “Septodont Case Studies Collection” to share their experience and the benefits of using these innovations in your daily practice.

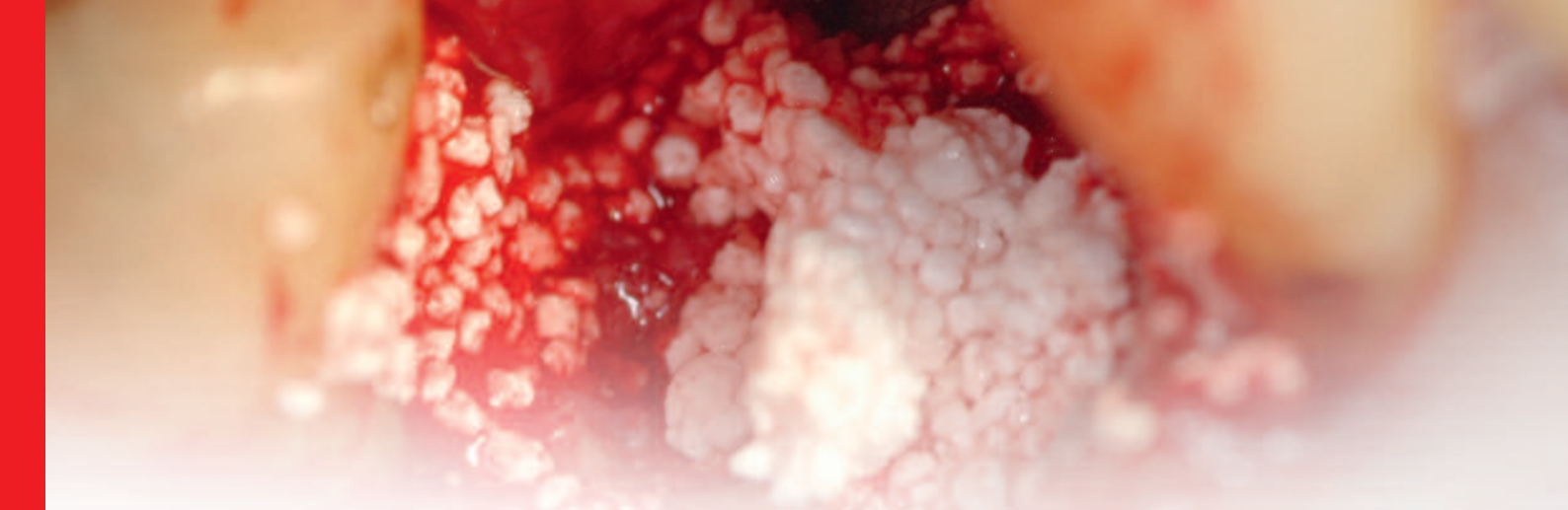
This Collection consists in a series of case reports and is published on a regular basis.

The seventh issue is dedicated to two of Septodont’s innovative products:

- R.T.R., an easy-to-use synthetic bone grafting material. In addition to its ability to provide an optimal osteoconductive environment to promote the growth of new dense bone, R.T.R. comes in 3 different presentations to suit all the clinical situations.
- Biodentine™, the first biocompatible and bioactive dentin replacement material. Biodentine™ uniqueness not only lies in its innovative bioactive and “pulp-protective” chemistry, but also in its universal application, both in the crown and in the root.

Content

	<p>Biomaterials for bone regeneration in oral surgery: A multicenter study to evaluate the clinical application of “R.T.R.”</p> <p>P. Brunamonti Binello, G. Galvagna, M. Galli, M. Labanca</p>	04
	<p>Bone regeneration with β-tricalcium phosphate (R.T.R.) in post-extraction sockets</p> <p>O. H. Arribasplata Loconi</p>	12
	<p>Restoration of the deep carious lesion</p> <p>S. Banerji</p>	22
	<p>Solution to a pulp chamber perforation: Use of Biodentine™</p> <p>I. Lorenzo</p>	25



Biomaterials for bone regeneration in oral surgery:

A multicenter study to evaluate the clinical application of “R.T.R.” (β-Tricalcium Phosphate)

Paolo Brunamonti Binello: Consultant Professor, University of Genoa

Giuseppe Galvagna: Private practice, Catania, Italy

Massimo Galli: Private practice, Pistoia, Italy

Mauro Labanca: Consultant Professor in Oral Surgery and Anatomy, Milan, Italy

In Literature there isn't any conflicting data about the clinical results obtained in Oral Surgery for bone regeneration using Biomaterials of either animal or synthetic origin.⁽¹⁾ What is the most important, however, is the creation of a microenvironment suitable for the proliferation and differentiation of hard tissues, such as to successfully promote the regeneration of new bone at the implant-prosthetic purposes.⁽¹⁻²⁾

For this reason, therefore, the Authors always prefer the use of synthetic materials with reduced risk of inflammation and complete absence of potential cross infections.⁽¹⁾

The Goal of this study is, therefore, to illustrate - through a case series - short term results of a multicenter research on bone regeneration in Oral Surgery by using an heterologous filling material that consists of β-Tricalcium Phosphate, called R.T.R.

Introduction

International Literature about bone regeneration in implant dentistry describes many different available surgical techniques and the following are the principal:

- Guided Bone Regeneration (G.B.R.)
- Bone Grafting
- Osteogenic Distractions

Each of the above mentioned methods, while presenting different and precise application limits (mostly related to the type of defect and

the surgical technique), turned out to be predictable if done correctly.⁽³⁾

The Literature data, then, show how - osteogenic distractions aside - the use of a biomaterial (regardless of its origin, whether animal or synthetic) is helpful if not indispensable to the attainment of an adequate clinical outcome.⁽⁴⁾

Finally, the use of semi-permeable barriers - whether or not absorbable membranes - rather than metal grids, in order to maintain a suitable

space, has proved indispensable in G.B.R., while it is still extremely discussed in other regenerative techniques.⁽⁵⁾

In fact, when we speak about Biomaterials in Regenerative Oral Surgery it is appropriate to make a distinction between the following elements:

- Semi-permeable membranes: they allow the stabilization of cloth and the selection of cell lines that will colonize the bone defect (space maintainer = maintenance of biological space).
- Filling material: Support the membrane and act as a "scaffold" for the migration, growth and differentiation of pre-osteoblasts into osteoblasts.

To contribute to the regeneration process, here are the following basic mechanisms of Osteo-

genesis, understood as a budding center of deputies to the new bone genesis:

- Osteoinduction: stimulation of the differentiation of mesenchymal cells in preosteoblasts.
- Osteoconduction: biological scaffold as a support to new cells in the differentiation process.

It is deduced that the new bone tissue formation occurs if the following organic conditions exist:

- Availability of mesenchymal cells capable of differentiating following the osteoinductive input
- Presence of osteoinductive input ("Osteoinductive Boost"), which initiates the differentiation of mesenchymal preosteoblasts in osteoblasts
- Existence of an osteoconductive environment that promotes the colonization and proliferation of graft.

R.T.R. (β -tricalcium phosphate)

Except for autologous bone, on the fundamental concepts of Osteogenesis, remains today still open the debate as to which type of currently available bone grafting material is the best.⁽⁶⁾

Given that, the Authors have carried out a multi-center research about clinical application of a synthetic filler (already known for years on the market) based on β -Tricalcium Phosphate for bone regenerative purposes, called "R.T.R." (Resorbable Tissue Replacement).⁽⁶⁾

The $\text{Ca}_3(\text{PO}_4)_2$ powder (treated with naphthalene and subsequently compacted by sintering) form the β -tricalcium phosphate, with macropores of a diameter between 100 and 300 microns ideal, that is, for the Osteoconduction.⁽⁶⁾

This heterologous biomaterial, once placed, is completely absorbed in 6 or 9 months, and replaced by new bone.⁽⁶⁻⁷⁾

Recent studies on large crestal defects show a significant increase in the regeneration with β -Tricalcium Phosphate already after 2 weeks compared to the other control sites, thereby proving the effectiveness of this filling material.⁽⁷⁾

During resorption, in addition, β -Tricalcium Phosphate provides with Ca ions and phosphate

into the site of regeneration: this creates an ideal ionic concentration with an alkaline pH, which stimulates the activation of alkaline phosphatase enzyme, which is essential to the ossification process.⁽⁶⁻⁸⁾

Then, all resources of this study and the attention of the authors are focused on the use of β -Tricalcium Phosphate called "R.T.R." basically because this synthetic biomaterial would possess - as a prerequisite - all the features that a generic filling material should have -with the exception of Osteoinduction.⁽⁶⁻⁷⁻⁸⁾

These characteristics may be summarized as follows:

- High biocompatibility and minimum autoimmune response
- Bio-inert (absence of local inflammatory reaction)
- Ideal time of resorption for the type of bone defect
- Total reabsorption
- Excellent osteoconductivity
- Good packaging
- High handling during surgery
- Absolutely no risk of cross-infection transmission

In particular, since “R.T.R.” is completely resorbable over a period of time, reasonably useful for important bone defects resolution, the authors think “R.T.R.” is particularly appropriate for all regenerations conducted for the purpose of

implant-prosthetic rehabilitation, in contrast with many other filling materials that do not resorb completely - and allow only a repair instead of a healing of the bone defect.⁽⁸⁻⁹⁾

Materials and methods

This multicenter Study provides for the regeneration of bone tissue with β -tricalcium phosphate “R.T.R.” in patients with a residual bone defect of the maxillary and with implant-prosthetic rehabilitation purposes.

The selection of patients is randomized. However, in order to standardize the number of cases, this random selection requires that patients have the following basic requirements:

- Aged between 20 and 60 years
- Either male or female
- Non-smokers
- In good general health
- Having at least a residual crestal bone defect

Regarding the type of defect, it is deliberately excluded to standardize the same, in terms of morphology and etiopathogenesis, in order to verify the regenerative effectiveness of “R.T.R.” in different conditions of bone atrophy (and, therefore, of different “regenerative thrusts”).

It is, therefore, decided to treat the following clinical situations:

- Post-extractive sites
- Bone regeneration around implants placed in areas with deficiencies in bone or post-extraction
- Overall G.B.R. (sinus lift or major bone defects)

Case series

The Authors, from 4 different cities and from different working situations (private practice, hospital and private clinic) have treated 12 patients with the following bone defects:

- N 3 peri-implant defects
- N 2 sinus floor lifts
- N 4 post extractive sockets
- N 3 bone defects of various types

In all cases, the patients were subjected to antibiotic therapy with 200 mg / day of Doxycycline (in 2 doses daily beginning the day before surgery up to 8 days after the intervention), to daily repeated rinses with chlorhexidine and therapy with FANS as needed (Ibuprofen 800 mg / day in single-dose).

Case Report no.1

The first is a case report of a 54-year-old male patient, in good health general conditions, with a mandibular residual cyst in area 46. (*Fig. 1-2-3*) In accordance with the patient, we opted for an intervention of Partsh II, filling the remaining cavity with R.T.R. granules without using semi-

permeable membranes. (*Fig. 4-5-6-7-8*)

About 6 months after the first surgery, the next step will involve the placement of one implant. The local objective examination and routine radiographic examination showed a good healing short-term. (*Fig. 9-10-11*)

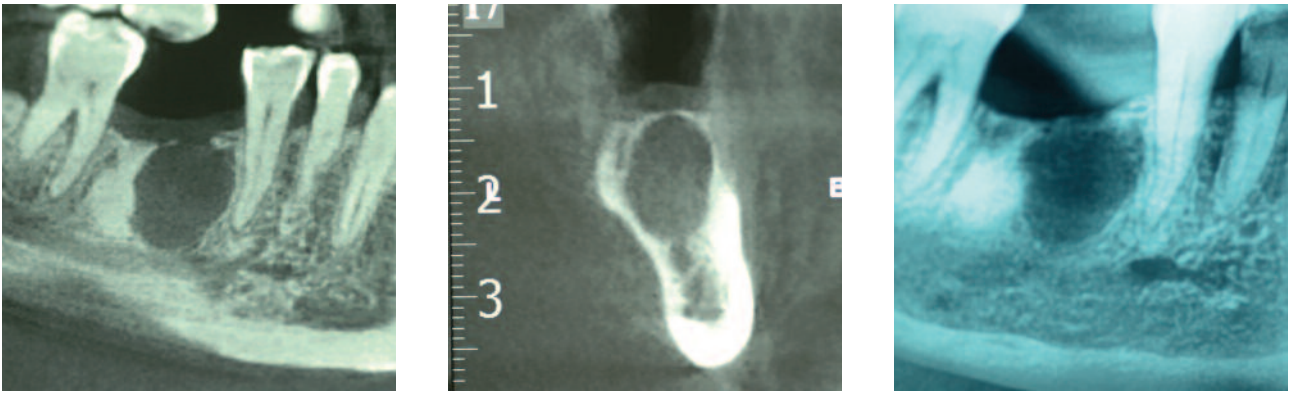

Fig. 1-2-3: Mandibular residual cyst in area 46.

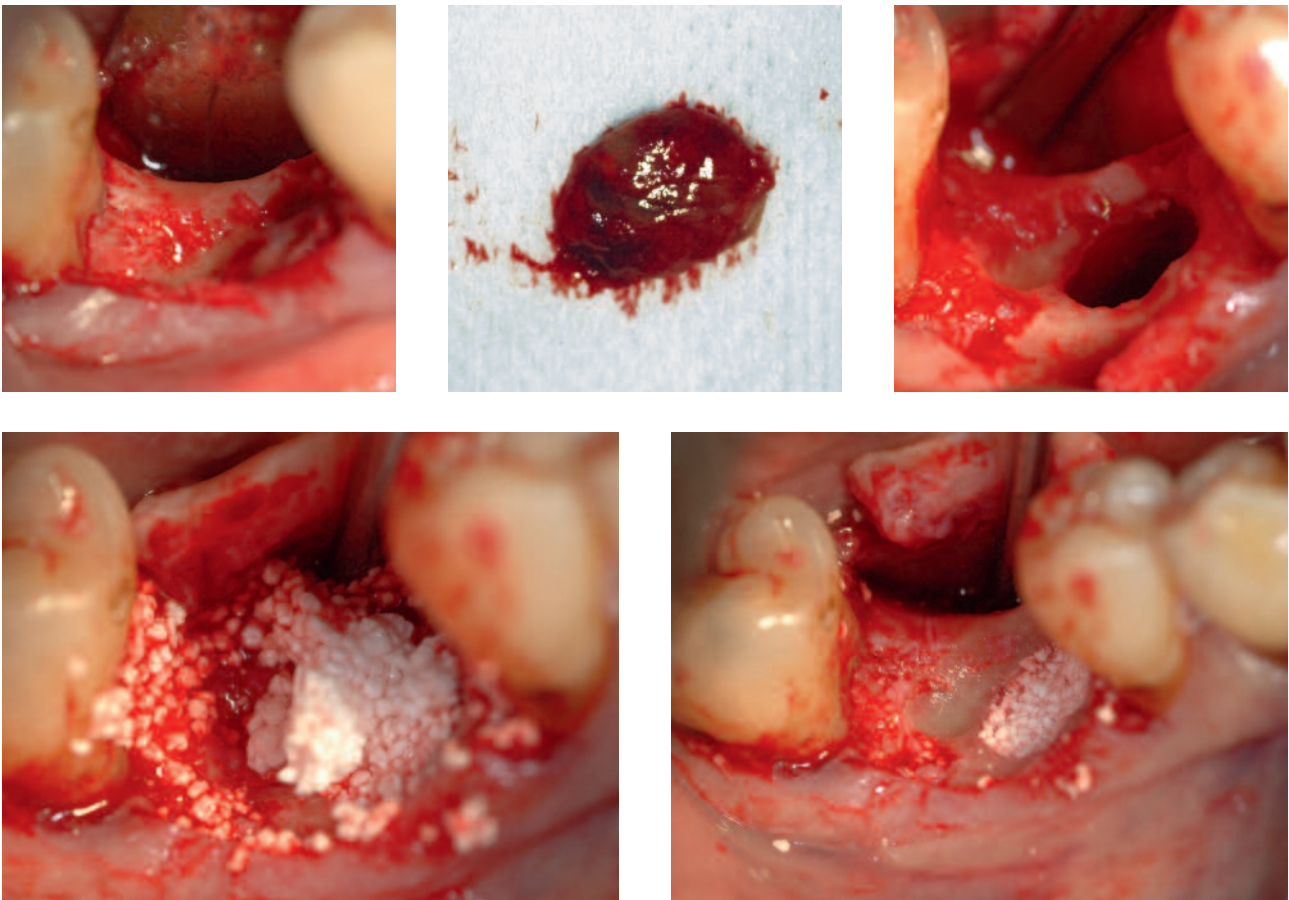


Fig. 4-5-6-7-8: Intervention of Partsh II and filling of the remaining cavity with R.T.R. without using semi-permeable membranes.

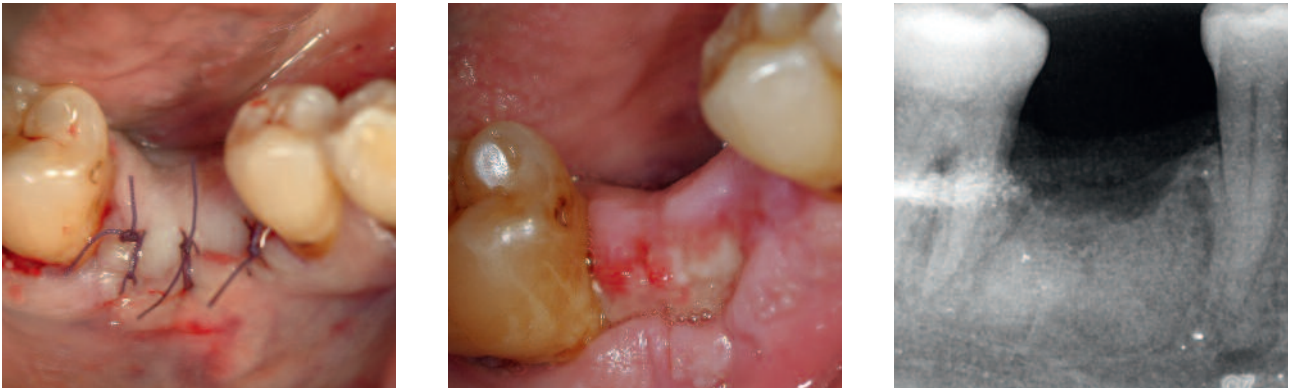

Fig. 9-10-11: The local objective examination and routine radiographic examination showed a good healing short-term.

Case Report no.2

The second case report is a 45-year-old female patient, in good general health conditions with edentulous in area 25-26 and progressive atrophy of the corresponding alveolar process. (Fig. 12-13)

In accordance with the patient, by full-thickness mucosal flap in the area 25-26, we opted for a transcrestal sinus floor lift with a R.T.R. graft and simultaneous placement of two fixtures. In this case R.T.R. has been used also as a filling material around implants contextually.

For this case the syringe form of R.T.R. has been chosen.

The fixtures had a good primary stability, equal to about 60 newtons. (Fig. 14-15)

The subsequent exposition of the implants and the beginning of the prosthetic phase will be managed about 6 months after sinus lift procedure.

The good health of the superficial soft tissues and surveys Rx screening show the excellent health of deep tissues in short term. (Fig. 16-17)

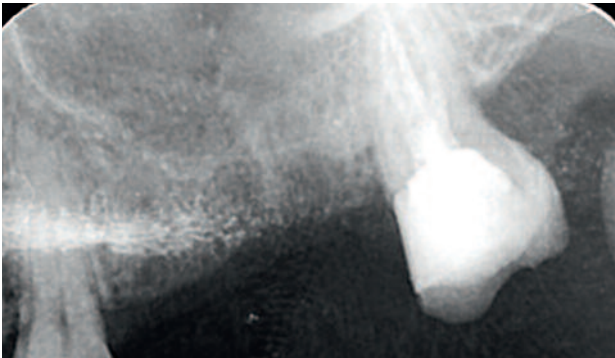


Fig. 12-13: Edentulism in area 25, 26 with partial atrophy of the alveolar process residue.

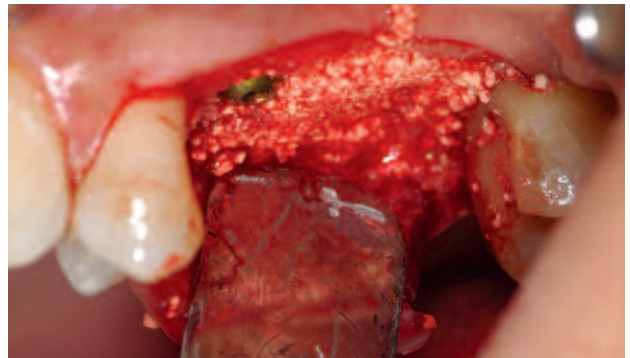
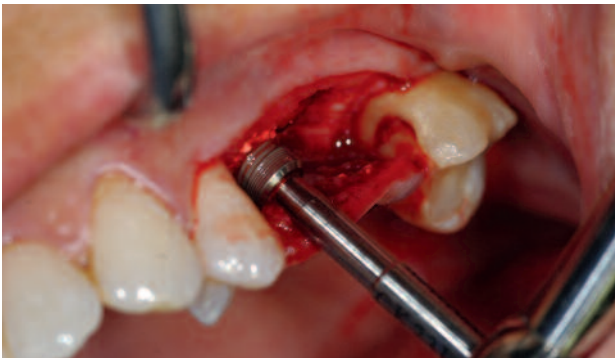
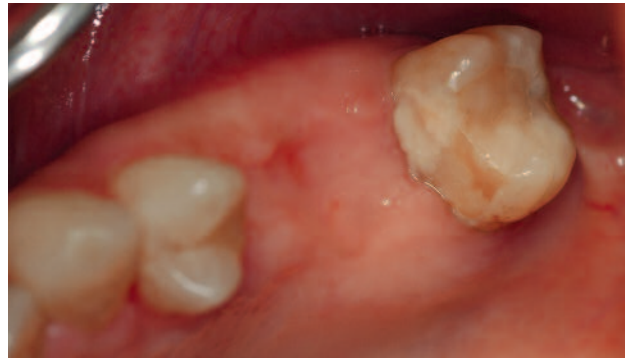
Fig. 14-15: Full-thickness mucosal flap in the area 25-26 and transcrestal sinus floor lift with a R.T.R. graft to a simultaneous placement of two fixtures. R.T.R. has been used also as a filler around implants.

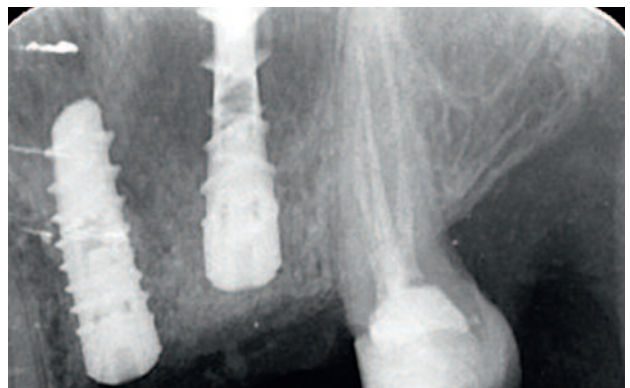
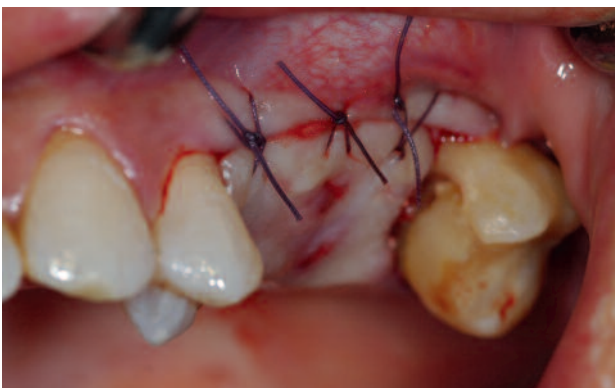
Fig. 16-17: The good health of the superficial soft tissues and surveys Rx screening show the excellent health of deep tissues in short term.

Case Report no.3

The third case report involves a 52-year-old female patient, in good general health conditions, who has been subject to avulsion of the elements 16 and 17, because they were irreparably compromised and extremely symptomatic. (Fig. 18-19-20)

In area 16, for regenerative purposes, has been

executed a graft of R.T.R., presented in a cone with collagen. (Fig. 21-22-23-24-25)

About 6 months following R.T.R. graft will be positioned an implant.

Also in this clinical case as in the others the local objective examination and the Rx screening showed an excellent recovery in the short term.

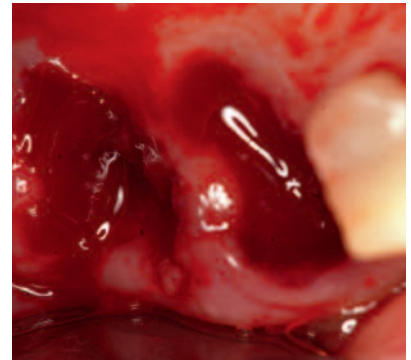
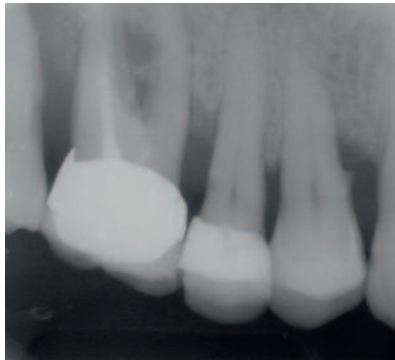
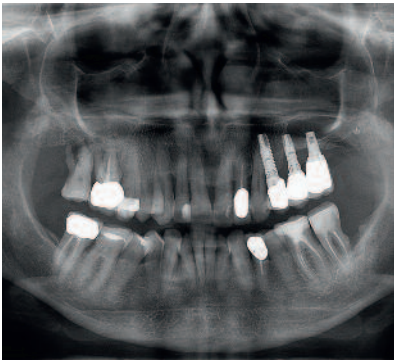


Fig. 18-19-20: Avulsion of the elements 16 and 17 due to a severe periodontal defect.

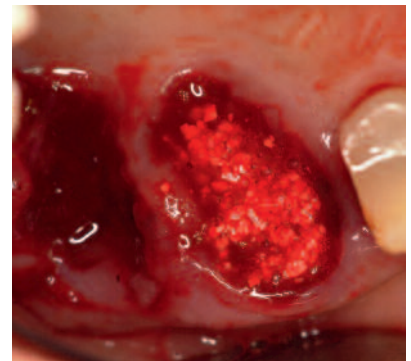
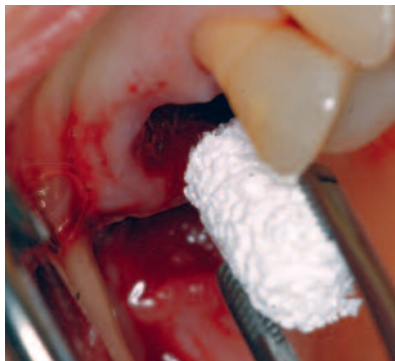
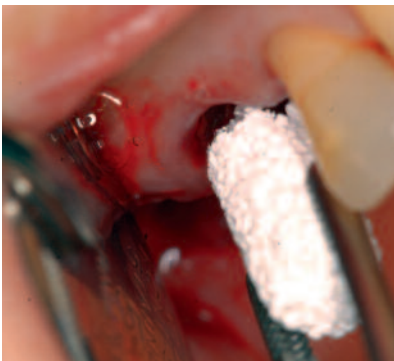
Fig. 21-22-23: In area 16, for regenerative purposes, has been executed a graft of R.T.R.

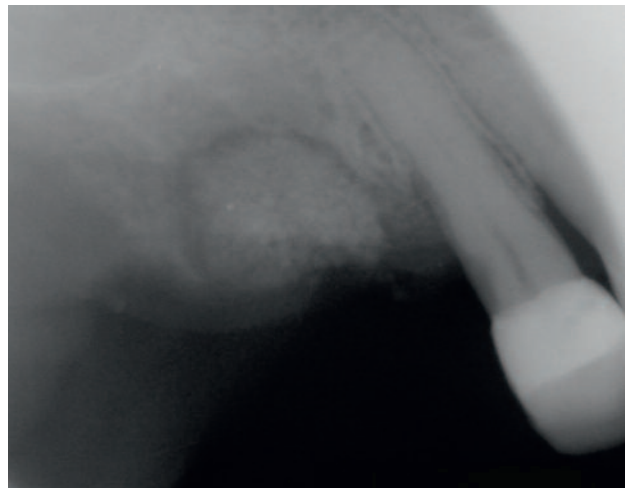
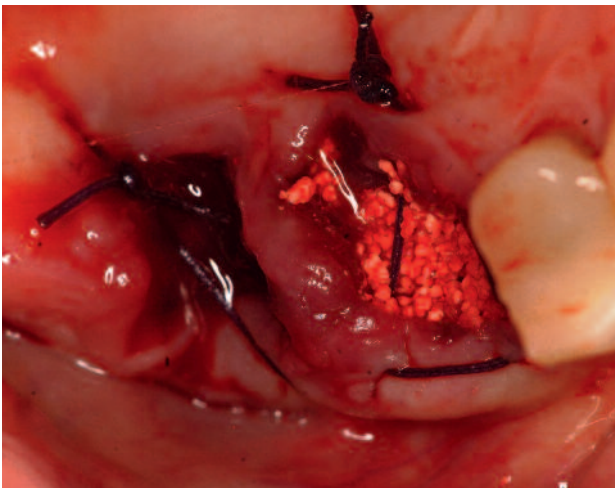


Fig. 24-25: Immediate post op clinical and radiological situation.

Discussion

The post-surgical follow-up in the short term (which provides an objective local examination and Rx control after 8 days and also in following weeks after the first surgical step) showed that in all cases treated were found the following items:

- Good immediate healing of superficial soft tissues
- Excellent radiographic condition of deep tissues
- Absence of autoimmune reactions
- Absence of local reactive inflammation
- Absence of excessive bleeding

The authors also confirm that R.T.R. material, besides having a packaging extremely functional, has expressed high qualities of practicality and manageability during the surgical procedure, in its mode of use, application and compaction (in all the forms of packaging).

The on-going research, currently in the initial phase, involves a series of stages, in which will also be performed (if and where possible) the implant-prosthetic rehabilitation of bone defects treated and, if possible, a histological evaluation suitable to document the degree of absorption and regeneration.⁽¹⁰⁻¹¹⁾

Conclusion

The interesting initial and partial results obtained to date are encouraging for the authors to continue the study in progress.

The goal remains to propose a predictable therapeutic solution, though alternative and not a replacement of the other existing and fully described in the Literature.⁽¹²⁻¹³⁻¹⁴⁻¹⁵⁻¹⁶⁾



Authors (left to right)

Mauro Labanca: From 2001 to 2005: Creator and Director of the very first Italian course “Anatomical surgery with Cadaver lab”. From 2006 up to date: Director of the course of “Anatomical surgery with Cadaver lab” at the Institute of Anatomy at the University of Wien, Austria. 2006: Creator and Director of the first Master of Marketing and Communications in Medicine and Private Dentistry at IULM University (Libera Università di Lingue e Comunicazione) in Milan, Italy. From 2007 up to date: International Consultant in Dentistry for MEDACorp, Leerink Swann LLC Boston, MA, USA. From 2007 up to date: Consultant Professor of Oral Surgery in the department of Dentistry at “Vita e Salute University” - S. Raffaele Hospital - Milan, Italy. From 2008 up to date: Consultant Professor of Anatomy in the Department of Medicine at the University of Brescia, Italy. 2009: Co-Founder and vice President of the Italian Society for the study of Oro-Facial Pain (SISDO). 2011: Founder and President of the “Labanca Open Academy” (LOA) devoted to the improvement of all aspects of Dentistry. Created to have an open network among all participants of his courses. From 2012: Visiting professor at the Periodontology Department of the “Universitat Internacional de Catalunya”, Barcellona, Spain.

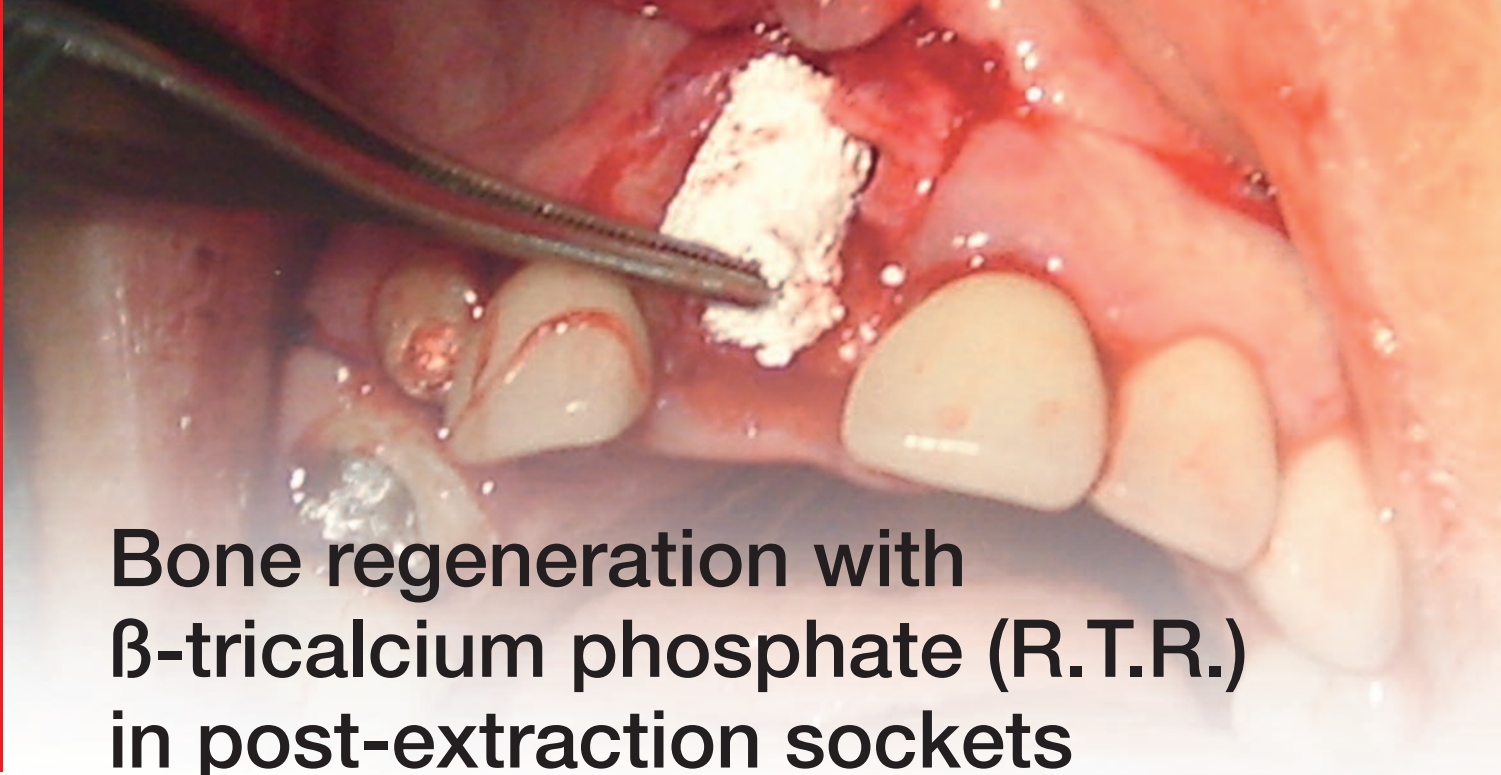
Paolo Brunamonti Binello: Consultant Professor, University of Genoa. Executive Doctor “Galliera Hospital”, Genoa, Italy

Giuseppe Galvagna: Private practitioner, Catania, Italy

Massimo Galli: Oral surgeon and private practitioner, Pistoia, Italy

References

01. Labanca M, Leonida A, Rodella FL. Natural or synthetic biomaterials in Dentistry: Science and ethic as criteria for their use. *Implantologia* 2008; 1:9-23
02. Nociti FH Jr, Machado MA, Stefani CM, Sallum EA, Sallum AW. Absorbable versus nonabsorbable membranes and bone grafts in the treatment of ligature-induced per-implants defects in dogs. Part I. A clinical investigation. *Clinical Oral Implants Research* 2001;2:115-120.
03. Hardwick R, Scantlebury T, Sanchez R, Whitley N, Ambruster J. Membrane design criteria for guided bone regeneration of the alveolar ridge. In: Buser D, Dahlin C, Schenk RK, eds. *Guided bone regeneration in implant dentistry*. Chicago, IL: Quintessence. 1st edition, 1994;101- 136.
04. Dahlin C, Linde A, Gottlow J, Nyman S. Healing of bone defects by guided tissue regeneration. *Plastic and Reconstructive Surgery* 1988;81:672-676.
05. Hockers T, Abensur D, Valentini P, Legrand R, Hammerle CH. The combined use of bioresorbable membranes and xenografts or autografts in the treatment of bone defects around implants. A study in beagle dogs. *Clinical Oral Implants Research* 1999;6:487-498.
06. Coetzee AS. Regeneration of bone in the presence of calcium sulfate. *Arch Otolaryngol* 1980;106:405-409.
07. Irrigary J. A study of atomic elements diffusion in coral after implantation in vivo. *Publication de Biomat Bordeaux, France* 1987:241-248.
08. Guillemin G. The use of coral as bone graft substitute. *Journal of Biomedical Materials Research* 1987;21:557-567.
09. Gielkens PF, Bos RR, Raghoobar GM, Stegenga B. Is there evidence that barrier membranes prevent bone resorption in autologous bone graft during the healing period? A systematic review. *Int J Oral Maxillofac Implants* 2007;22(3):390-398.
10. Raymond AY, Sotirios V. Comparative evaluation of decalcified and non-decalcified freeze-dried bone allograft in Rhesus monkeys. I. Histologic findings. *Journal of Periodontology* 2005 Jan;76(1):57-65.
11. Sommerland S, Mackenzie D, Johansson C, Atwell R. Guided bone augmentation around a titanium bone-anchored hearing aid implant in canine calvarium: an initial comparison of two barrier membranes. *Clin Implant Dent Relat Res* 2007;9(1):22-33.
12. Maeda H, Kasuga T. Control of silicon species released from poly(lactic acid)-polydimethylsiloxane hybrid membranes. *J Biomed Mater Res A* 2007; [Epub ahead of print].
13. Mattout P, Mattout C. Conditions for success in guided bone regeneration: retrospective study on 376 implant sites. *Journal of Periodontology* 2000;12:1904-1909.
14. Chou AM, Sae-Lim V, Hutmacher DW, Lim TM.: Tissue engineering of a periodontal ligament-alveolar bone graft construct. *Int J Oral Maxillofac Implants* 2006;21(4):526-534.
15. Kohal RJ, Hurzeler MB. Bioresorbable barrier membranes for guided bone regeneration around dental implants. *Schweiz Monatsschr Zahnmed.* 2002;12:1222-1229.
16. Hartman GA, Arnold R.M, Mills MP, Cochran DL, Melloing JT. Clinical and histologic evaluation of inorganic bovine bone collagen with or without a collagen barrier. *International Journal Periodontics Restorative Dentistry* 2004;2:127-135.



Bone regeneration with β -tricalcium phosphate (R.T.R.) in post-extraction sockets

Prof. Oscar Hernán Arribasplata Loconi

Department of Odontology, Norbert Wiener University, Lima, Peru

Two clinical cases are presented in which β -tricalcium phosphate "R.T.R." (Septodont) was used for post-extraction bone regeneration to preserve the alveolar ridge in height and width for future dental implants placement. Resorption of the filling material is demonstrated by a histological study as well as good clinical and tomographic results.

Introduction

The dimensions of the alveolar ridge may be seriously affected following dental extraction as a result of normal alveolar bone remodelling.^{1,2} Although the bone loss occurs in both the horizontal and vertical aspects, greater bone loss is observed in the horizontal dimension.³

Schropp et al.¹ found that the greatest loss of alveolar height occurred during the first 3 months and less than 50% of the width of the ridge was lost after 1 year. Other studies observed losses amounting to 40% of height and 60% of width after only 6 months.^{3,4}

During the 80's and in the early 90's, bone grafting procedures were commonly performed using autogenous bone or fresh frozen allografts, but the advent of efficient and safe processing and the sterilisation techniques led to an increasing use of bone graft substitutes for the procedures of periodontal regeneration and

alveolar ridge augmentation.^{7,8}

The main advantages in using bone grafting substitutes are their unlimited availability and the reduction in the morbidity associated with the harvest of autologous bone at a second intraoral or extraoral surgical site.⁹

The development of synthetic or combined biological-synthetic alloplastic materials for bone regeneration has become more widespread during recent years. This type of material may integrate or resorb completely, forming lamellar bone at the site. Inorganic ceramics based on calcium phosphate (α -tricalcium phosphate, β -tricalcium phosphate and hydroxyapatite) contrast with bone regeneration materials of biological origin in the sense that the synthetic materials have their physical and crystallographic characteristics clearly defined in addition to the chemical properties (chemical composition and purity).¹¹

β -tricalcium phosphate has been used in various studies in animals and in humans in order to demonstrate its efficiency as a bone regeneration biomaterial.

Aims

Histological, tomographic and clinical evaluation of alveolar ridge preservation in width and height following the insertion of β -tricalcium phosphate "R.T.R". (Septodont) in post-extraction sockets for future dental implants placement.

Materials & Methods

In order to be able to observe whether the alloplastic filling material, β -tricalcium phosphate "R.T.R." (Septodont) resorbs completely, a histological study was performed 12 months after grafting the material in the alveolar socket, the biopsy being done at the time of implant placement.

This material was used in cone presentation when the post-extraction socket was well preserved by atraumatic extractions. However the material was used in syringe presentation combined with resorbable membranes in bone defects in which the vestibular bone plates were lost. Absorbable polyglycolic acid sutures of 4/0 zeroes with a sharp needle 3/8 circle were used. The grafted sockets were observed radiographically after 6 and 12 months.

Results

The material's ability to resorb and form new bone yielded excellent results, demonstrated by a histological study done 12 months after placement, as well as by a case of bone regeneration using a membrane (imminent vestibular destruction), for which a control tomography was performed after 18 months showing excellent results.

The results obtained in this study confirm the main observations of other clinical and experimental studies performed any other groups of professionals.

Case Report no.1

A 29-year-old woman came with a fistula at the level of tooth 2.5; grade II tooth mobility. On X-ray examination, a radiopaque image was observed in the canal showing a post and core restoration; periapically, a radiolucent lesion was observed, potentially revealing an infectious process.

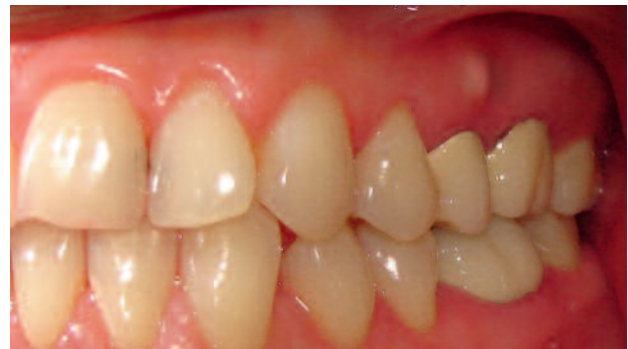

Fig. 1: Presence of the fistula at tooth 2.5.

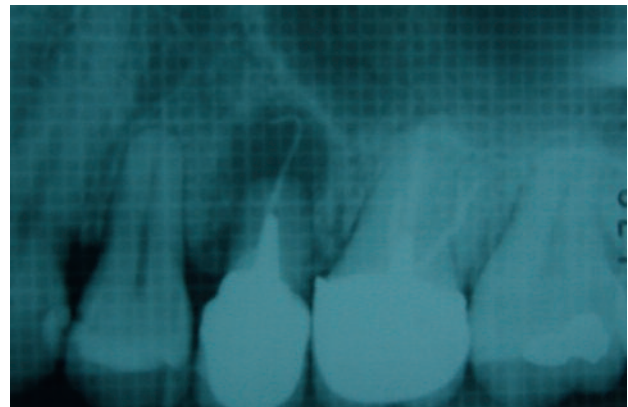


Fig. 2: Fistulography (cone no. 25).

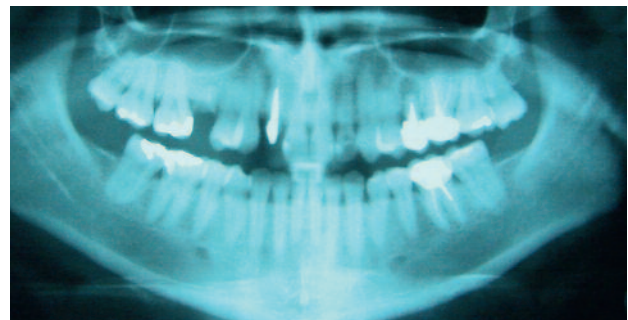


Fig. 3: Panoramic X-ray.

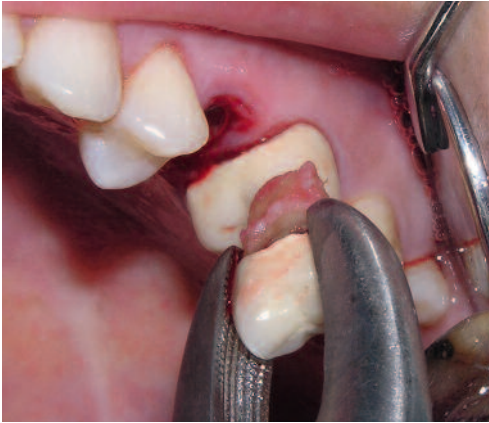


Fig. 4: Atraumatic extraction.

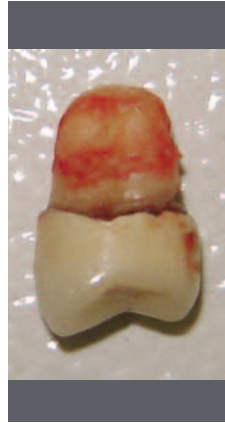

Fig. 5: Extracted tooth.



Fig. 6: β -tricalcium phosphate (R.T.R.).

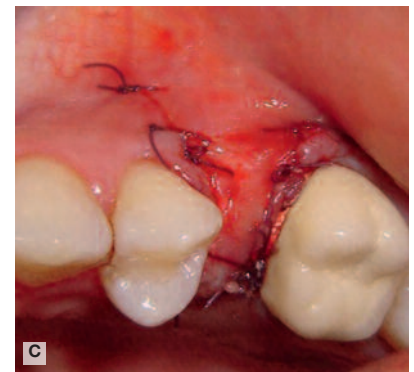
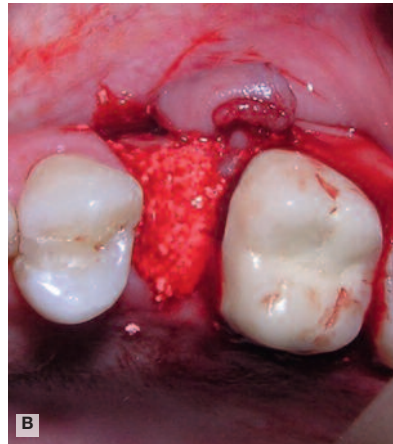
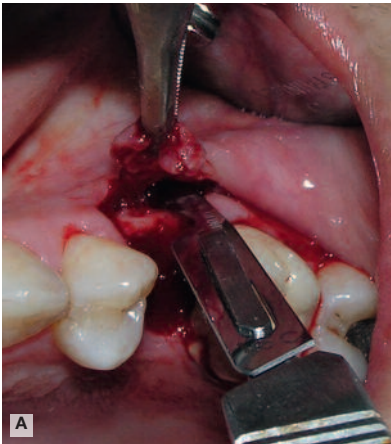


Fig. 7: a) Partial thickness flap, b) Placement of the β -tricalcium phosphate (R.T.R.) in the alveolar socket, c) Suturing of the flap with Vicryl 5/0 zeroes figure-of-eight sutures.

The tooth was extracted and the β -tricalcium phosphate filling material "R.T.R" (Septodont) was placed, without a membrane; a partial thickness flap was raised in order to cover the graft and the wound was sutured using 4/0 polyglycolic acid sutures with a sharp needle 3/8 circle.

She was prescribed: Amoxicillin 500 ml/clavulanic acid 125 mg once every 8 hours x 5 days. Ibuprofen 400 mg once every 8 hours for 3 days. Soft diet x 48 hours.

The sutures were removed after 2 weeks.

She was advised to get X-ray controls after 3, 6 and 12 months. After 12 months, the patient returned for consultation; she had been unable to do so before for reasons beyond her control. A clinical examination was performed (Fig. 8) in addition to a periapical X-ray with a metal mesh (grip). On the periapical X-ray done after 12 months a circumscribed radiopaque image, round in shape, was observed in the area of the graft as if it were apparently an encapsulation of the material (Fig. 9).

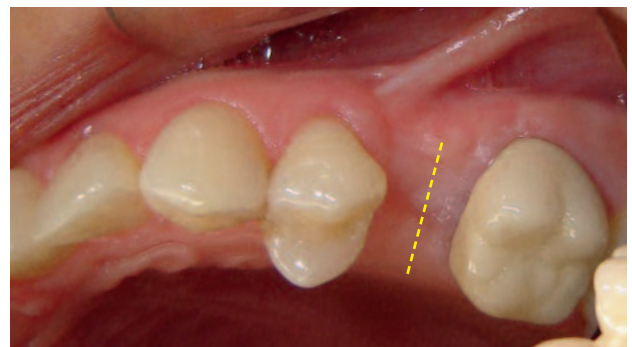

Fig. 8: Clinical examination (12 months).

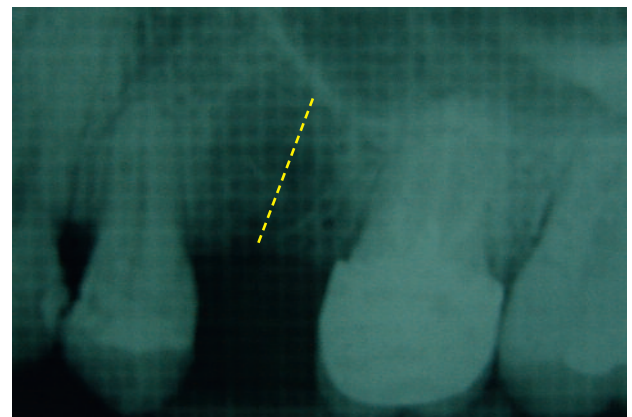

Fig. 9: Periapical X-ray (12 months).

After 12 months, it could be clinically observed how the alveolar ridge had been maintained both in width and height and in order to verify whether the β -tricalcium phosphate (R.T.R.) had resorbed completely, we took a sample from the area to be implanted and performed a histological study (Fig. 10).

The treatment plan was thoroughly implemented for a correct insertion and placement of the dental implant. We knew that computerised axial tomography would provide a more precise diagnosis with respect to bone width and height. However since a single dental implant was involved and moreover a fairly well preserved ridge was clinically observed, we used the clinical mapping method.

Doing our measurements, we had a palatine vestibular width of 8 mm and a width of 7 mm mesiodistally. The calculation of the height using the periapical X-ray done with metallic mesh (grip) and a parallel method gave us an approximation of the actual height, which was 10 mm. After obtaining all the measurements of 8x7x10mm, it was decided to perform maxillary sinus lift using Summer's technique.

Dental implant placement

Using a trephine drill 2 mm in diameter, we removed bone tissue from the alveolar ridge for its histological study in which we wanted to find out whether the β -tricalcium phosphate (R.T.R.) had resorbed completely. The sample was placed in 10% formocresol.

Then we positioned our surgical guide in order to perform the sequential drilling for implant placement, using helical drills; a control X-ray

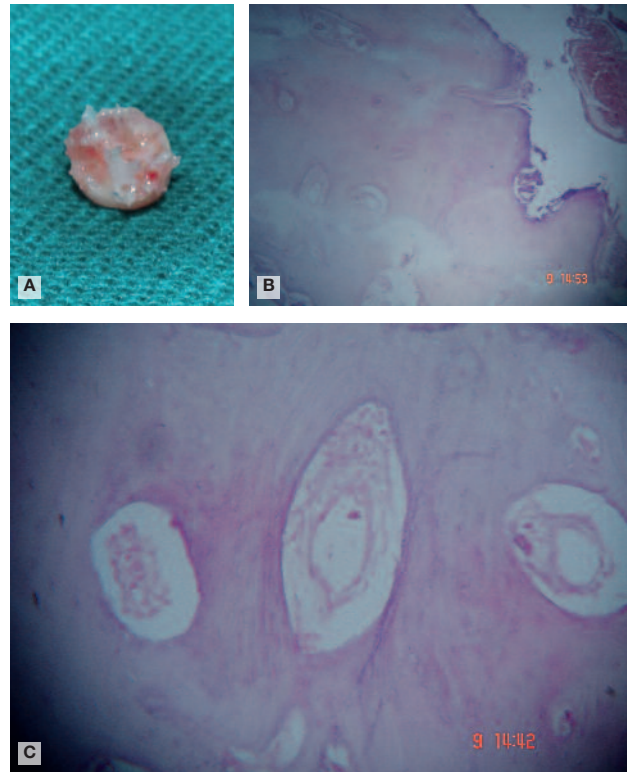


Fig. 10: a) Tissue sample, removed using a 2mm trephine drill, in the area in which the dental implant is to be inserted. b,c) Histological results after 12 months. Haematoxylin eosin tincture under light microscopy. New bone formation at the level of the β -tricalcium phosphate absorption site.

of the preparation was taken, inserting a paralleling pin in the alveolar socket (Fig. 12b), which showed us correct parallelism with the preparation; it was observed how the paralleling pin remained exactly 2 mm away from the sinus floor (Fig. 12c), since it was taken with a grip; then Summer's technique was performed approach to the Schneider membrane using osteotomes, from crestal bone leaving 1-2 mm of residual bone before the floor of the maxillary sinus¹³.

This dimension of bone was increased by means of pressure, pushing the membrane upwards

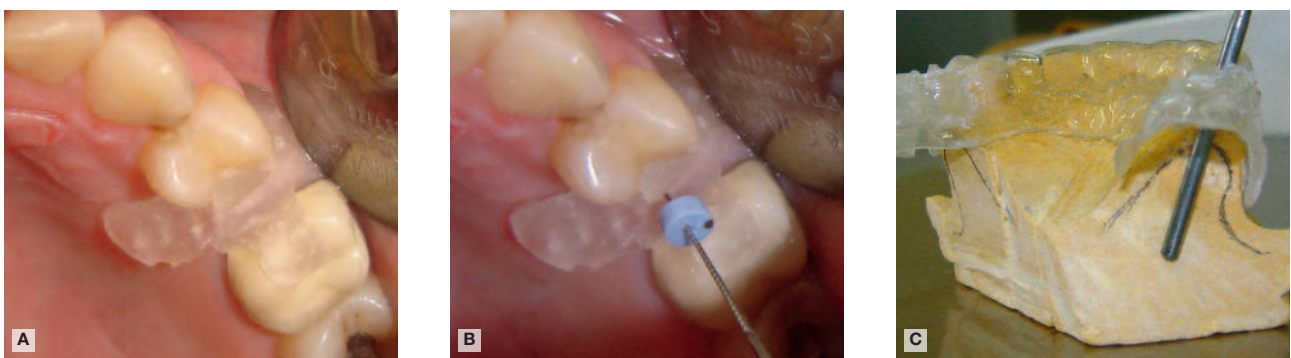


Fig. 11: Clinical mapping. a) Placement of the saddle-shaped acrylic on the area for taking of measurements, tooth 2.5. b) Taking of measurements (file no. 25). c) Transfer of measurements to the trimmed model.

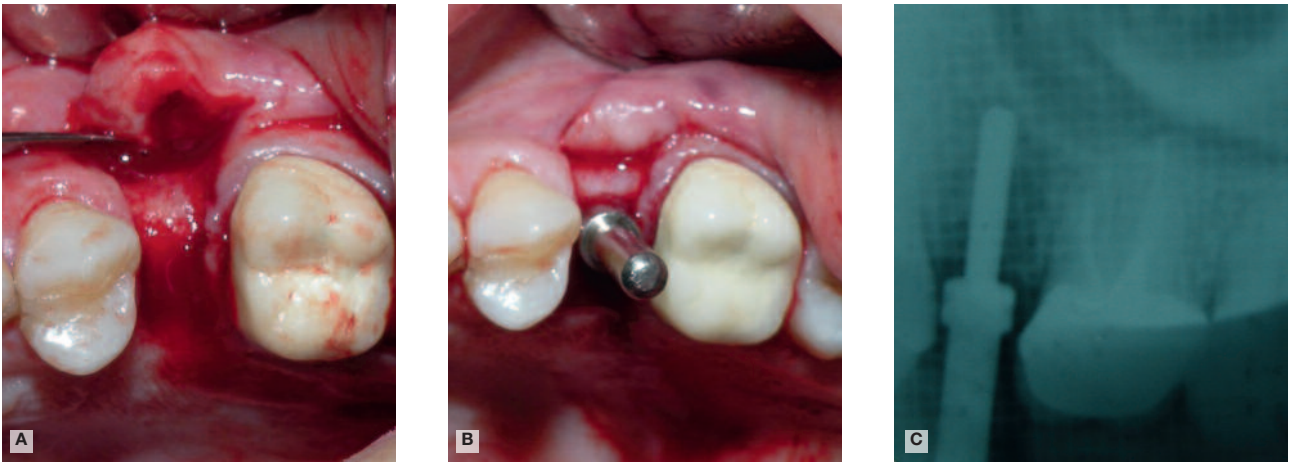

Fig. 12: Preparation for implant placement. a) Paracrestal incision and raising of the flap. b) Insertion of the paralleling pin. c) X-ray showing 2 mm before reaching the maxillary sinus.

without perforating the latter and creating the space required to place biomaterials or the implant.

Once the sinus floor elevation was achieved, which could allow a gain between 3 and 4 mm in height 13-15, the implant, Conexão of 11.5 x 4 mm cylindrical internal hexagon, was inserted; in this case we succeeded in elevating the sinus floor by 3.5 mm. (*Fig. 13*)

Finally, a partial thickness flap was performed with 2 liberating incisions in order to be able to confront the soft tissues in the palatine direction; figure-of-eight sutures and X (cross) sutures were inserted in order to protect the tissue and avoid collapse; the liberating incisions were

sutured with circumferential sutures. Vicryl 5/0 zeroes was used for synthesis (*Fig. 14 a*). The postoperative X-ray was performed confirming the elevation of the sinus floor by approx. 3.5 mm. (*Fig. 14b*)

She was prescribed: Amoxicillin 500 ml/clavulanic acid 125 mg once every 8 hours x 5 days. Ibuprofen 400 mg once every 8 hours for 3 days. Soft diet x 48 hours.

The sutures were removed after 2 weeks. The patient was advised to wait for 6 months for osseointegration. The results of the histological study showed bone neoformation with absence of β -tricalcium phosphate (R.T.R.) filling material.

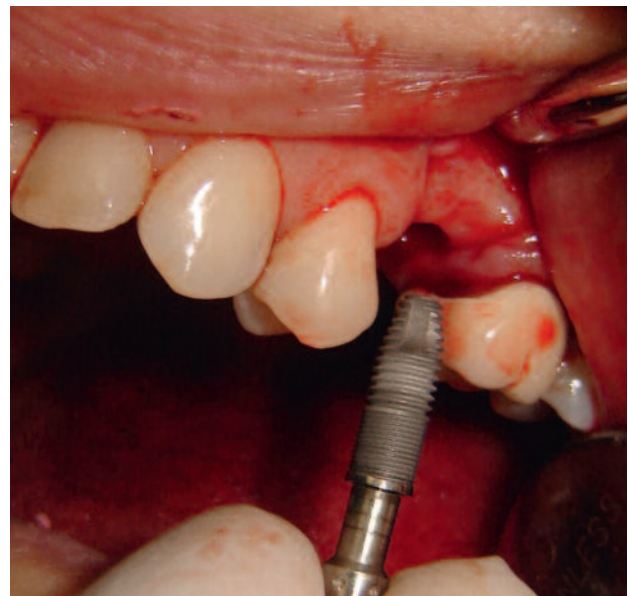
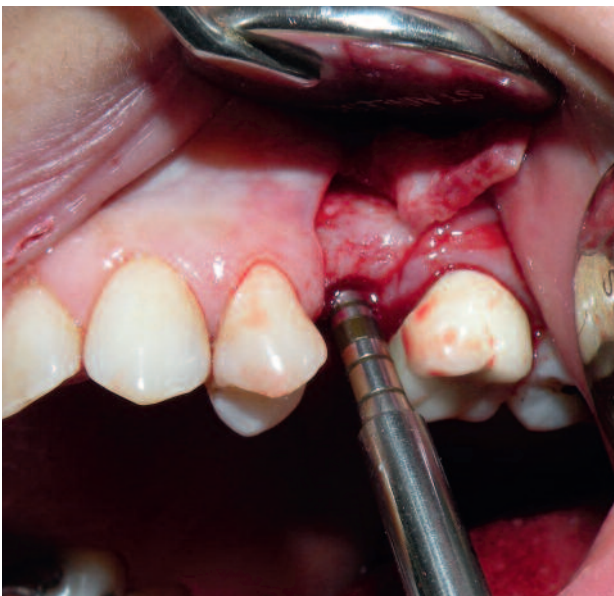
Fig. 13: Maxillary sinus lift with osteotomes (Summer's technique) and placement of the 11.5 x 4 cylindrical, internal connection Conexão implant.

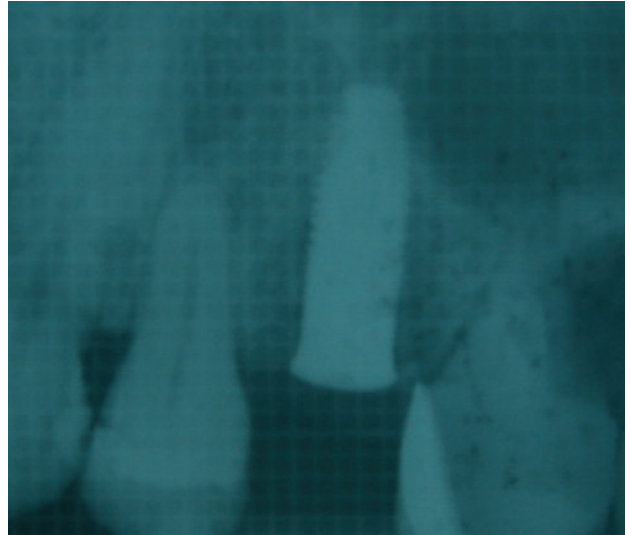
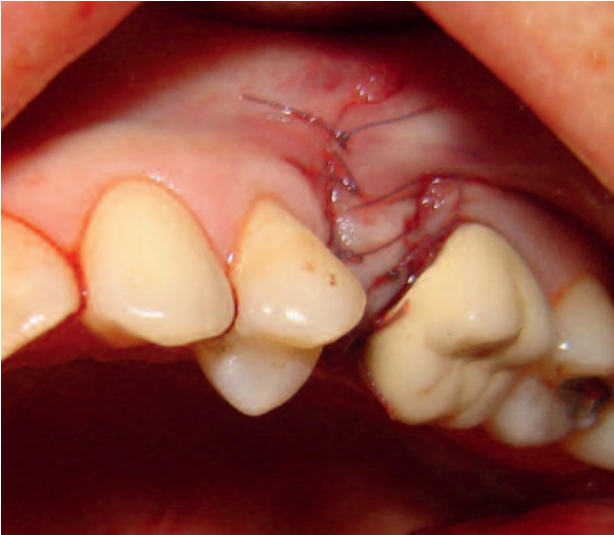

Fig. 14: Full thickness flap and suture with Vicryl 5/0 zeroes. g) Postoperative X-ray showing the 3.5 mm maxillary sinus lift achieved using Summer's technique.

Implant activation

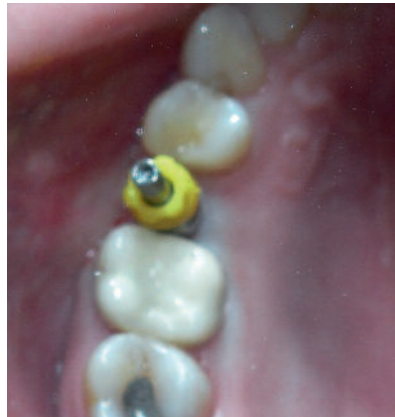
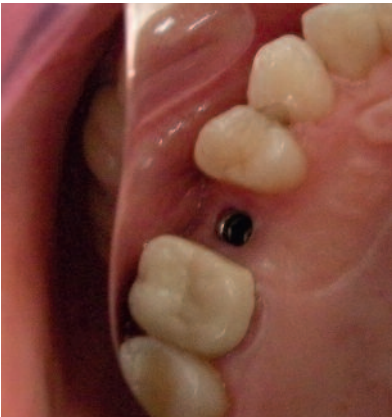
Fig. 15: Open-tray impression taking, application of transfer and analog on the impression.

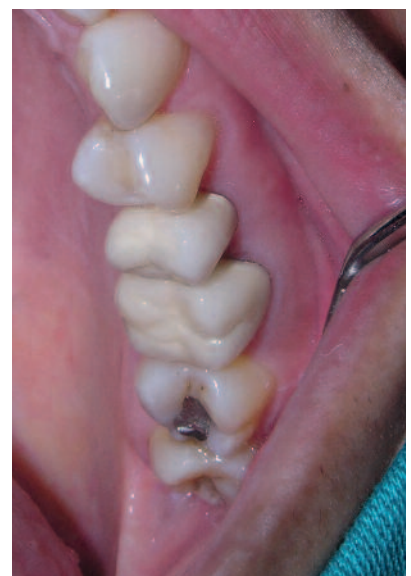
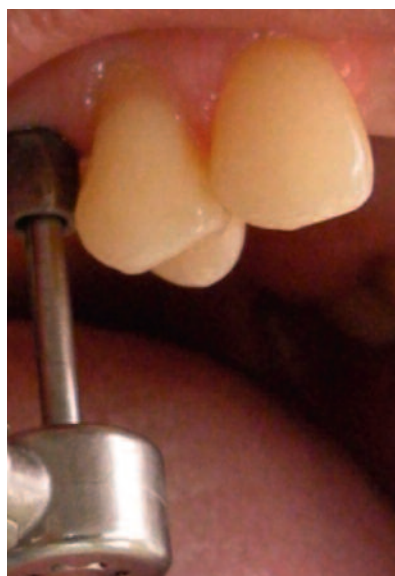
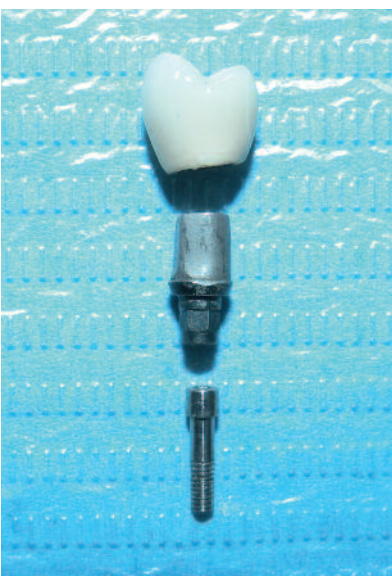Fig. 16: Prepared abutment and application of the porcelain crown.

Case Report no.2

A 54-year-old woman came with grade III tooth mobility at tooth 1.1. On X-ray examination, a radiopaque image was observed in the canal showing a post and core restoration. The patient presented with an obvious root fracture on clinical examination.

Atraumatic extraction of the tooth was performed, then the guided bone regeneration procedure with β -tricalcium phosphate (R.T.R. - Septodont)

was done, in addition to the use of a resorbable membrane. A partial thickness flap was performed in order to cover the graft and the membrane, the wound was sutured using 4/0 polyglycolic acid sutures with a sharp needle 3/8 circle. The sutures were removed after 2 weeks. She was recommended to get X-ray controls after 3, 6 and 12 months.

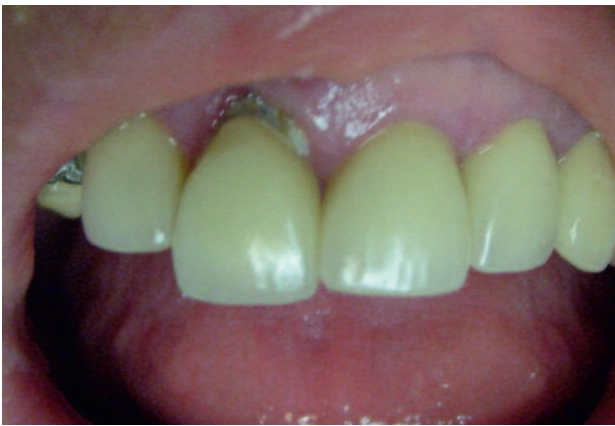

Fig. 1: Initial photo. Tooth 1.1 with extrusion and grade III mobility.

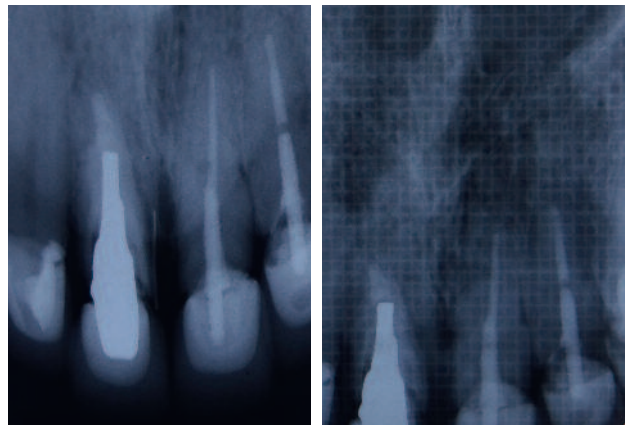


Fig. 2: Initial X-ray. a) Tooth 1.1, presence of an excessively wide post and core, the probable cause of root fracture. b) X-ray with grip.

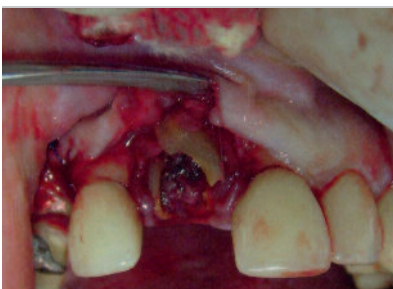


Fig. 3: The major root fracture can be confirmed when raising the full thickness flap.

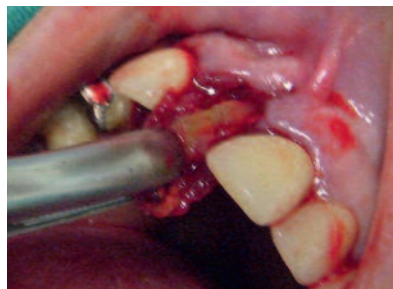

Fig. 4: Extraction of tooth 1.1, loss of the vestibular bone plate due to the fracture which remained for a long period in the mouth.

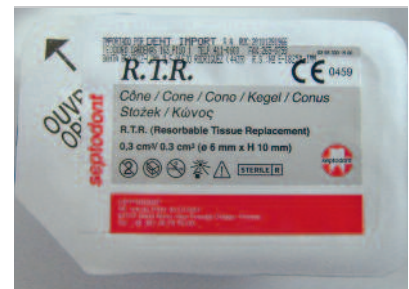

Fig. 5: R.T.R. in cone presentation.

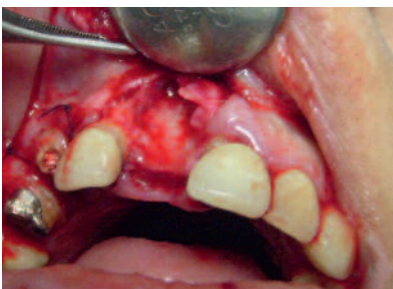

Fig. 6: Major vestibular bone loss.

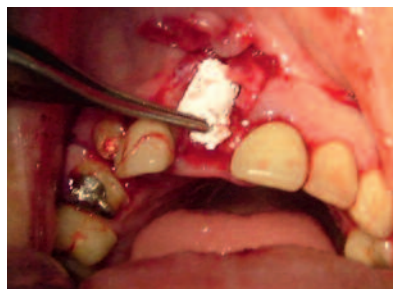

Fig. 7: Placement of the R.T.R. cone.

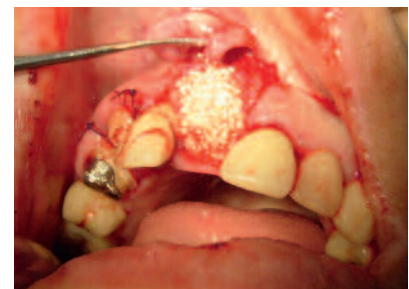

Fig. 8: Modelling of the R.T.R. cone.

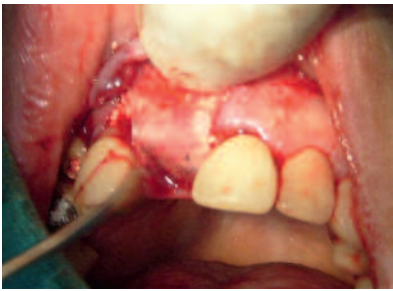

Fig. 9: Insertion of a collagen membrane due to an important vestibular bone loss.

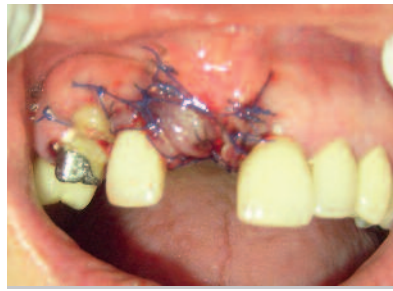

Fig. 10: Interrupted figure-of-eight sutures. A partial thickness flap was performed to cover the membrane.

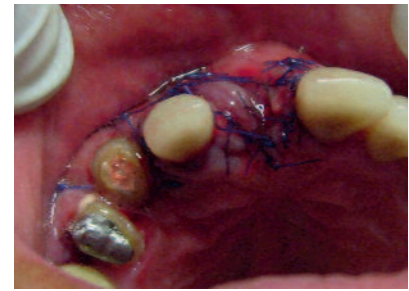


Fig. 11: Interrupted figure-of-eight sutures. Palatine view.

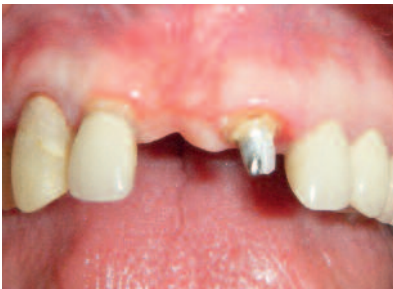

Fig. 12: Ridge preservation in width and height. The appearance of recessions at the level of teeth 1.2 - 2.2 had been explained to the patient before surgery.

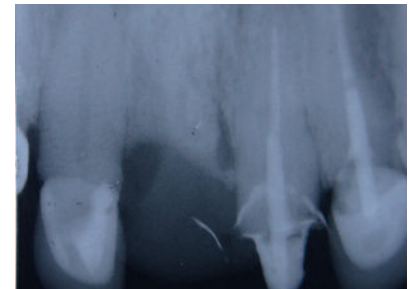
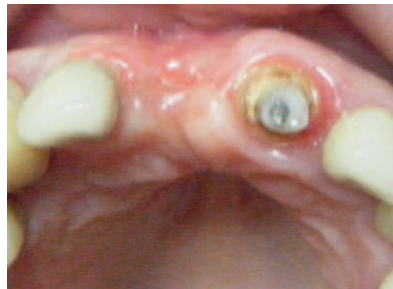

Fig. 13: Final X-ray.

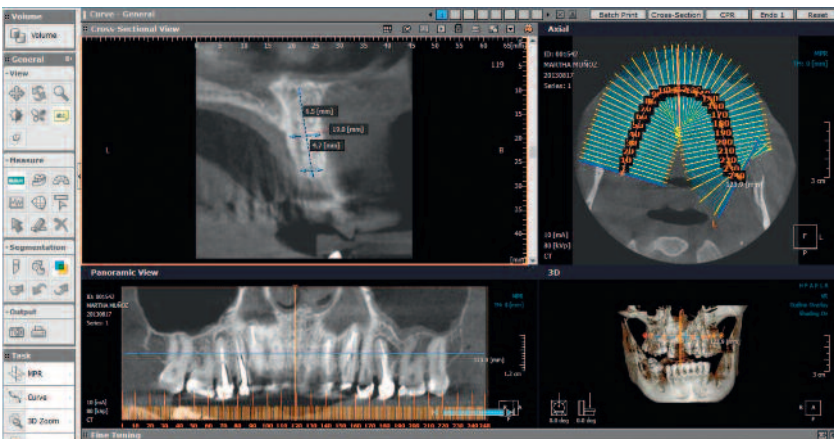


Fig. 14: Tomography 18 months after surgery in order to check bone regeneration before inserting a dental implant.

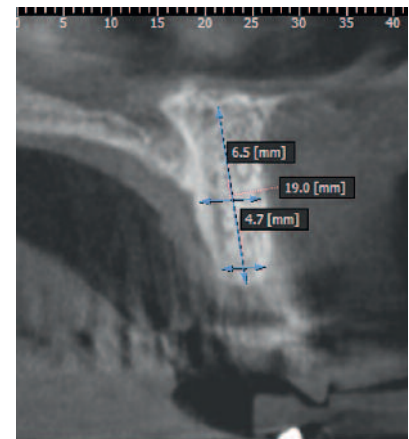


Fig. 15: Bone regeneration in the area corresponding to tooth 1.1 was visible.

Conclusion

- β -tricalcium phosphate (R.T.R.) has proven to be a good osteoconductive material for bone regeneration following the filling of a post-extraction socket, allowing the preservation of the alveolar ridge in order to place a dental implant.
- Its ability to resorb and form new bone yielded excellent results, demonstrated by a histological study done 12 months after placement, as well as by a case of bone regeneration

using a membrane, since vestibular destruction was imminent, where a control tomography was performed after 18 months showing excellent results.

- It is easy to use and handle.
- The results obtained in this project confirm the main observations of other clinical and experimental studies performed by any other groups of professionals.

References

01. Schropp L, Wenzel A, Kostopoulos L, Karring T. Bone healing and soft tissue contour changes following single-tooth extraction: A clinical and radiographic 12-month prospective study. *Int J Periodontics Restorative Dent* 2003;23:313-323.
02. Nevins M, Camelo M, De Paoli S, et al. A study of the fate of the buccal wall of extraction sockets of teeth with prominent roots. *Int J Periodontics Restorative Dent* 2006;26:19-29.
03. Lekovic V, Camargo PM, Klokkevold PR, et al. Preservation of alveolar bone in extraction sockets using bioabsorbable membranes. *J Periodontol* 1998; 69: 1044-1049.
04. Iasella JM, Greenwell H, Miller RL, et al. Ridge preservation with freeze-dried bone allograft and a collagen membrane compared to extraction alone for implant site development: A clinical and histologic study in humans. *J Periodontol* 2003;74:990-999.
05. Schallhorn RG, Hiatt WH, Boyce W. Iliac transplants in periodontal therapy. *J Periodontol* 1970;41:566-580.
06. Tonetti MS, Hammerle CH. Advances in bone augmentation to enable dental implant placement: Consensus Report of the Sixth European Workshop on Periodontology. *J Clin Periodontol* 2008;35:168-172.
07. Cortellini P, Bowers GM. Periodontal regeneration of intrabony defects: an evidence-based treatment approach. *Int J Periodontics Restorative Dent* 1995;15:128-145.
08. Mellonig JT, Bowers GM, Bright RW, Lawrence JJ. Clinical evaluation of freeze-dried bone allografts in periodontal osseous defects. *J Periodontol* 1976;47:125-131.
09. Rawashdeh MA, Telfah H. Secondary alveolar bone grafting: the dilemma of donor site selection and morbidity. *Br J Oral Maxillofac Surg* 2008;46:665-670.
10. Gustavo Avila-Ortiz; Satheesh Elangovan; Nadeem Karimbux. Bone Graft Substitutes for Periodontal Use Available in the United States. *Clinical Advances in Periodontics*; Copyright 2012. DOI: 10.1902/cap.2012.120043.
11. Horch HH, Sader R, Pautke C, Neff A, Deppe H, Kolk A. Synthetic, pure-phase β -tricalcium phosphate ceramic granules (Cerasorb) for bone regeneration in the reconstructive surgery of the jaws. *Int J Oral Maxillofac Surg*. 2006;35(8):708-13.



Author: Prof. Oscar Hernán Arribasplata Loconi

Studied Dentistry at the University Inca Garcilaso de la Vega. (Peru-2001).
Second Specialization in Periodontics and Implants at the University National of San Marcos (Peru-2010).

Master of Dentistry at the University Inca Garcilaso de la Vega (Peru-2011).

Certified in Orthodontics at the Dental Association of Peru (Lima-2005).

Certified in Teaching Strategies and competency assessment at the University Norbert Wiener (Peru-2012).

Post-Graduate Course in Forensic Dentistry at the University National of San Marcos (Peru-2011).

Post-Graduate Course in Auditing and Forensic Dentistry at the University Peruana Cayetano Heredia (Peru-2012).

Professor of Periodontology II, Theory and Practice at the University Norbert Wiener (Lima; 2010-2013).

Professor invited to the second specialty in Oral Rehabilitation at the University National of San Marcos (2012).

Ex-Professor of Periodontal Surgery at the University National of San Marcos (2010).

Publication of articles in the specialty of Periodontics.

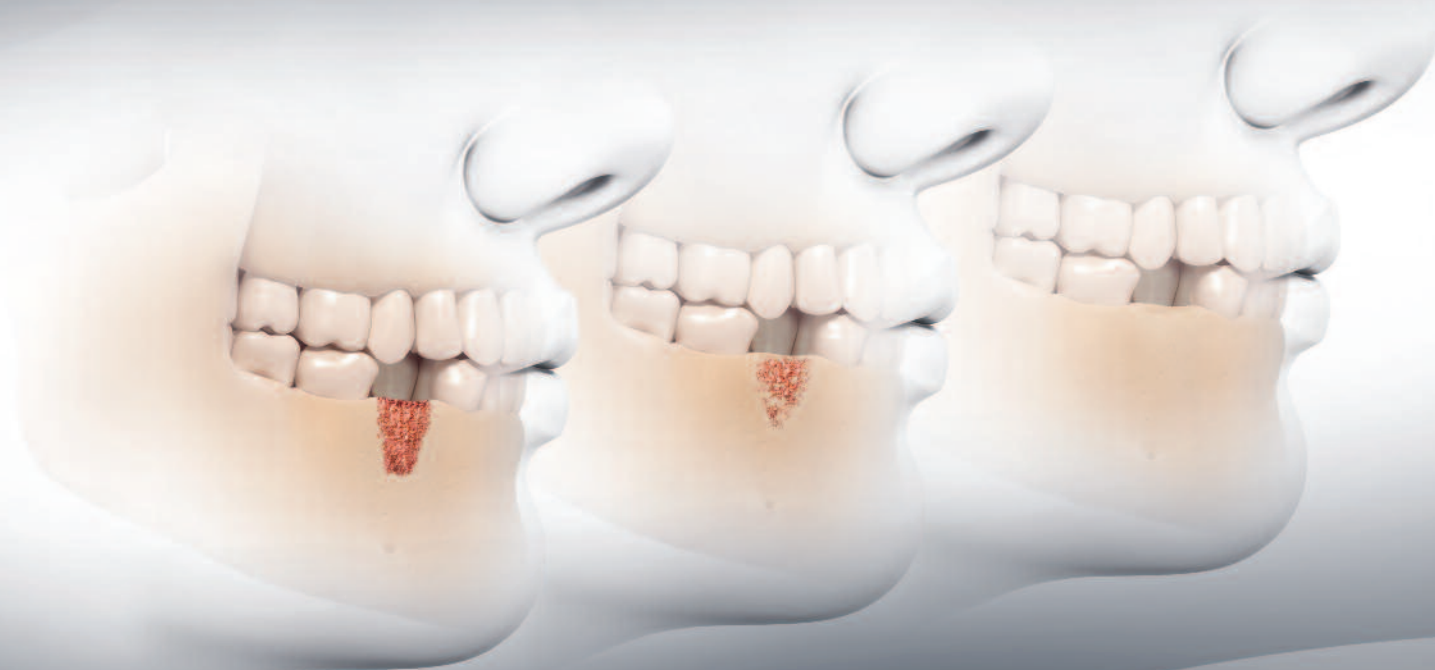Member of the Peruvian Association of Periodontology and Osseointegration.

Lecturer at National and International Conferences.

R.T.R.

Full resorption...

...Strong new bone formation



Cone



Syringe



Granules

R.T.R. (Resorbable Tissue Replacement) is a highly pure β -tricalcium phosphate bone grafting material that helps to safely create new bone formation following an extraction or any bone loss (intrabony defect, sinus-lift...).

- **Resorbs progressively and fully:** R.T.R. releases calcium and phosphate ions helping to promote strong new bone formation.
- **Regenerates natural bone growth.** Osteoconductive micro and macroporous structures foster dense new bone growth.
- **Restores volume:** R.T.R. renews the bone integrity within 3-6 months.
- **Available in 3 presentations** (Cone, Syringe, Granules) to suit all clinical situations.

Improve your patients' extraction therapy and bone loss repair to promote future implant success with R.T.R.

R.T.R. Cone contains collagen from bovine origin



Restoration of the deep carious lesion

Dr Subir Banerji

King's College London, United Kingdom

The loss of tooth tissue and its subsequent replacement has always posed a challenge for both the clinician and the Bio-material scientist. Whether lost by caries or as a result of the mechanical removal of diseased dentine, the substitution of dentine and enamel adequately to protect and support the tooth from further compromise and prevent a sequelae leading up towards endodontic treatment, is a desirable feature in a successful restoration.

Introduction

The importance of caries risk assessment has been well documented^{1,2,3} and in conjunction with preventative features^{4,5,6} is an integral part of the management process which influences the long term outcome. However the clinician is often faced with a situation as seen in *figure 1* where the caries is deep within the dentine in close proximity to the pulp and restorative intervention is required.

The issue here for both the clinician and the patient is the predictability and indeed the desirability to maintain pulpal health and vitality and

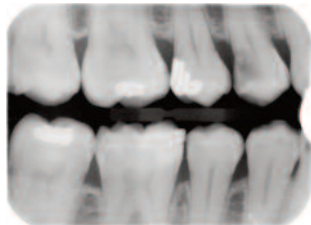


Fig. 1

therefore an accurate diagnosis of the pulpal status is advantageous. However the methods commonly available for such evaluations may not be totally reliable⁷. The partial removal of the caries mechanically has been well documented^{8,9,10} and this can help prevent iatrogenic

trauma to the pulp. Use of a dentine and subsequent enamel substitute is required to restore the cavity and currently a single material may not fulfil all the desired properties required.

A distinct benefit would also be if the material were to induce reparatory changes within the tissues as well as providing structural support and reliable adhesion. Biodentine™ (Septodont) has shown potential for regeneration of the dentine - pulpal complex^{11,12,13} as well as other desirable restorative properties for a dentine replacement material.

From a clinical prospective in general practice there is an advantage to be able to offer the patient with an option in the situation as depicted in *figure 1*. - A restorative approach that aims to repair and restore the lesion as well as have the potential for sustainability of the vitality of the tooth. Particularly when the periapical tissues show no radiographic signs of involvement¹⁴

nor any other conclusive diagnostic test result is obtained with regards the status of the pulp. In this particular case (tooth 14) the tooth was symptomless and there were no changes in the periapical tissues detectable from the periapical radiograph (*Fig. 2*). Furthermore normal responses to sensibility testing via cold and electrical stimuli were noted.

The caries was accessed and excavated as shown in *figure 3* and the cavity restored with Biodentine™ (*Fig. 4*).

After a period of waiting for 2 weeks (a shorter waiting time is possible as recommended by the manufacturer) the tooth was reviewed for symptoms and a normal response to sensibility testing was noted. A direct composite restoration was placed after the reduction of the Biodentine™ to accommodate the composite as an enamel substitute in a closed sandwich protocol. *Figure 5* shows the composite restoration at the 2-year recall.

The adhesion of the material is via micro-mechanical anchorage of the mineral tags within the dentinal tubules. At the interfacial layer called the “mineral infiltration zone,” the alkaline caustic effect of the calcium silicate cement’s hydration products degrades the collagenous component of the interfacial dentine resulting in this infiltration¹³. Compare this with glass ionomers where at the dentine-restorative interface the polyacrylic and tartaric acids and their salts characterise the penetration of the material¹⁵.

The mixing and handling is crucial to the success of the material and protection during the setting mechanism is required. As shown in another case below (*Fig. 6-9*), after setting of the material, it is reduced and a bulk left behind to fulfil the requirements of a dentine substitute and allowing adequate room for the composite material.

Patient acceptability of the material is high in the author’s experience. Facilitated by the potential advantage of the prospect that endodontic treatment could be avoided in a deep carious cavity. Proper discussion regarding the benefits and indications for the use of this material with the patient is an important step towards obtaining informed consent.

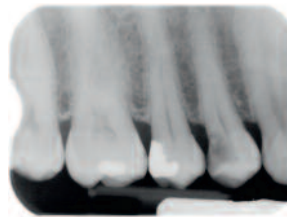


Fig. 2

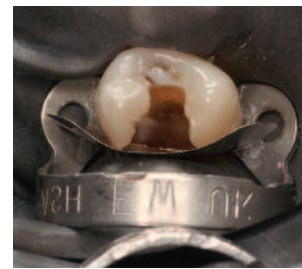

Fig. 3

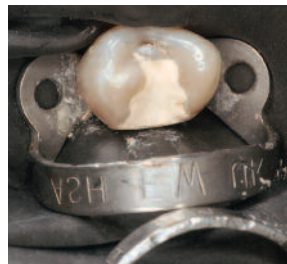

Fig. 4

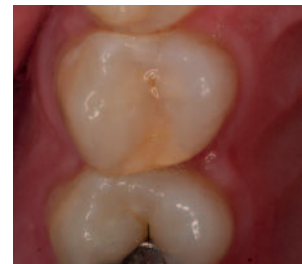

Fig. 5

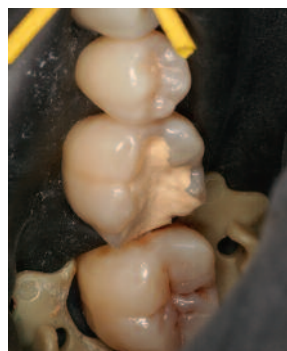

Fig. 6

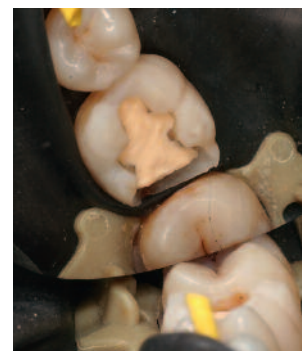

Fig. 7

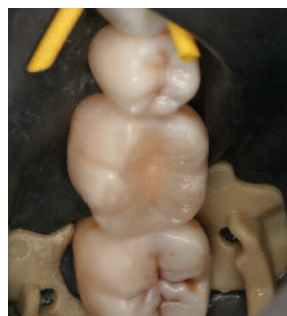

Fig. 8

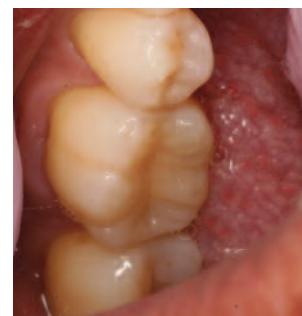

Fig. 9

Due to its properties and characteristics, Biodentine™ has applications in a variety of other clinical situations with particular indications in the management of endodontic perforations and cracked teeth. With the welcome drive towards minimal intervention, development of “biomimetic” materials that promote healing alongside established disease prevention protocols, a comprehensive successful approach towards patient management becomes achievable.

References

01. Yanase RT, Le HH. Caries management by risk assessment care paths for prosthodontic patients: oral microbial control and management. *Dent Clin North Am*. 2014 Jan;58(1):227-45.
02. Steinberg S. Adding caries diagnosis to caries risk assessment: the next step in caries management by risk assessment (CAMBRA). *Compend Contin Educ Dent*. 2009 Oct;30(8):522, 524-6
03. Mejàre I et al. Caries risk assessment. A systematic review. *Acta Odontol Scand*. 2013 Sep 2. [Epub ahead of print].
04. Weyant RJ et al. Topical fluoride for caries prevention: Executive summary of the updated clinical recommendations and supporting systematic review. *J Am Dent Assoc*. 2013 Nov;144(11):1279-91
05. Newbrun E. Topical fluorides in caries prevention and management: a North American perspective. *J Dent Educ*. 2001 Oct;65(10):1078-83.
06. Riley JL 3rd et al. Preferences for caries prevention agents in adult patients: findings from the dental practice-based research network. *Community Dent Oral Epidemiol*. 2010 Aug;38(4):360-70.
07. Dastmalchi N et al. Comparison of the efficacy of a custom-made pulse oximeter probe with digital electric pulp tester, cold spray, and rubber cup for assessing pulp vitality. *J Endod*. 2012 Sep;38(9):1182-6
08. Schwendicke F et al. Incomplete caries removal: a systematic review and meta-analysis. *J Dent Res*. 2013 Apr;92(4):306-14
09. Maltz M et al. Incomplete caries removal in deep lesions: a 10-year prospective study. *Am J Dent*. 2011 Aug;24(4):211-4.
10. Maltz M et al. Partial removal of carious dentine: a multicenter randomized controlled trial and 18-month follow-up results. *Caries Res*. 2013;47(2):103-9
11. Marjorie Zanini et al. Biodentine Induces Immortalized Murine Pulp Cell Differentiation into Odontoblast-like Cells and Stimulates Biomineralization. *J Endod* 2012;38:1220–1226)
12. Laurent P et al. Induction of specific cell responses to a Ca3-SiO5-based posterior restorative material. *Dent Mater* 2008;24:1486-1494.
13. Camilleri J. Investigation of Biodentine as dentine replacement material. *Journal of dentistry* 41 (2013) 600–610
14. Bender IB. Reversible and irreversible painful pulpitis: diagnosis and treatment. *Aust Endod J*. 2000 Apr;26(1):10-4.
15. Atmeh AR et al. Dentin- cement interfacial interaction: calcium silicates and polyalkenoates. *Journal of Dental Research* 2012;91:454–9.

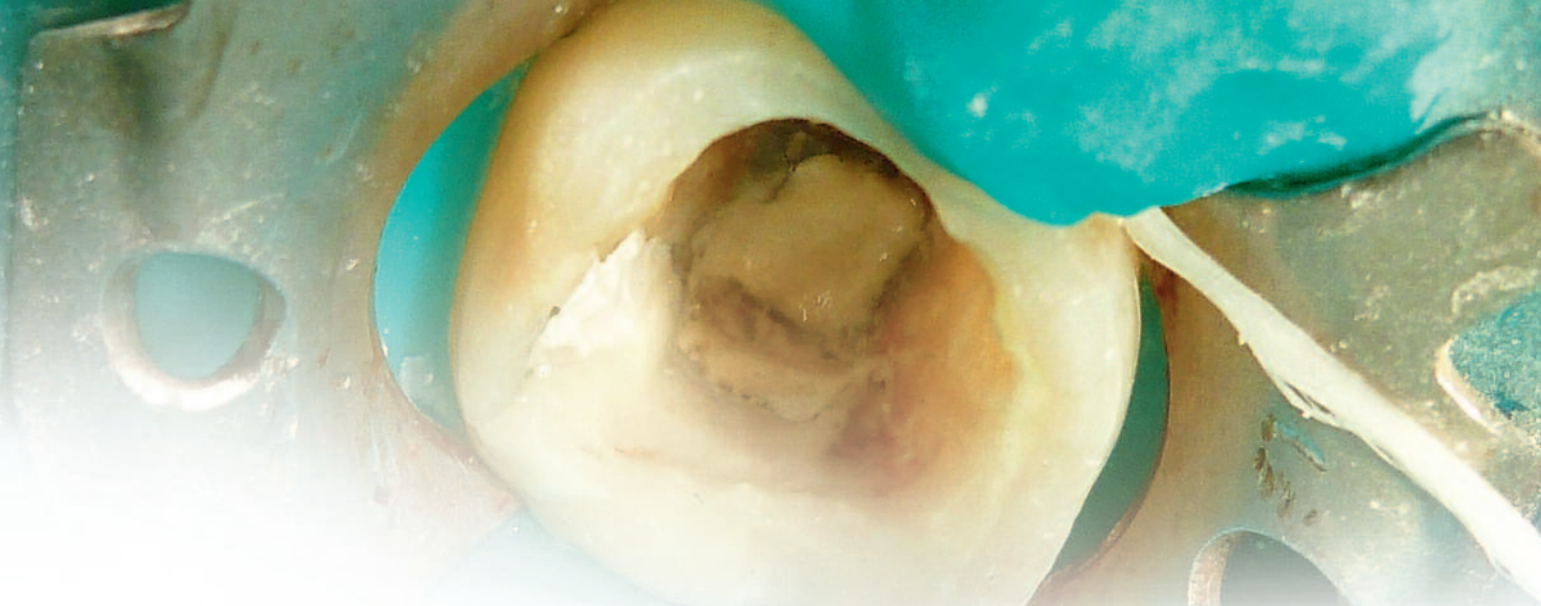

Author: Dr Subir Banerji

Dr Subir Banerji qualified with a Bachelor of Dental Surgery from The University of Newcastle Upon Tyne Dental School, UK.

He completed an advanced course in Restorative Dentistry at The Eastman Dental Hospital, London and his Fellowship of the International Congress of Oral Implantologists. He gained his Masters in Clinical Dentistry (Fixed and Removable Prosthodontics) from the University of London.

In addition to his Private Practice in London he is the Programme Director for the MSc in Aesthetic Dentistry, a Senior Postgraduate Teacher on the Master's in Clinical Dentistry (fixed and removable Prosthodontics) programme and a former Senior Clinical Teacher at the Department of Primary Dental Care at King's College London Dental Institute. He lectures nationally and internationally and has several publications to his credit in peer reviewed International journals. He has authored a chapter on patient examination and assessment for the book "Essentials in Aesthetic Dentistry", to be published by Elsevier in 2013/14. He is also the author of the academic units on Implants, Posterior Composites and Tooth Wear for the Master's programmes at King's College. He has conducted several Postgraduate and Master's level courses in aesthetics, implants, composites, fixed and removable prosthodontics and occlusion in the UK, Europe, Australia and India. He is also an examiner for both Undergraduate and Postgraduate programmes.



Solution to a pulp chamber perforation: Use of Biodentine™

Prof. Dr. Irene Lorenzo
University of Montevideo, Uruguay

A female patient of 47 years of age, without any particularities from a general point of view, attends consultation with masticatory disturbances in the left lower jaw.

Previous treatment is observed in tooth 46 on X-ray examination, with a radiopaque substance in the pulp chamber and an inter-radicular lesion. (*Fig. 1*). During inspection, sensitivities are present on vertical percussion of tooth 46 and a restoration with disadapted margins is observed.

It is decided to eliminate the restoration completely; complete isolation is performed with rubber dam and once the material present in the pulp chamber has been removed using ultrasonic tips, an amalgam is noticed on the floor of the pulp chamber (*Fig. 2, 3, 4*).

After its removal by means of ultrasonic tips, granulation tissue is exposed with bleeding and pain on pressure (*Fig. 5*).

Its elimination is performed under local anesthesia using a dentin excavator selected according to the size of the lesion, performing a clean cut as shallow as possible until hard tissue is encountered. The hemorrhage is inhibited under pressure with cotton swabs soaked with calcium hydroxide and saline solution, alternating with chlorhexidine irrigation.

Once hemostasis is achieved, a calcium hydroxide paste is inserted, filling the cavity, prepared with saline solution and with addition of Ciri

Otic (Roemmers) for control of inflammation and infection.

The patient comes back after 7 days reporting absence of symptoms. After complete isolation with rubber dam and the removal of the temporary filling and copious irrigation with 2.5% sodium hypochlorite, it is possible to view the lesion site and its size.

Biodentine™ preparation is performed according to the manufacturer's specifications and the cavity is filled layer by layer without pressure (*Fig. 6*).

The material is placed beyond the perforation space in order to reinforce the floor of the pulp chamber which was also affected, after insertion of sterile cotton swabs at the entrance of each canal as a protection to ensure they would not be blocked by the repair material.

Once the material is set, the canals are unblocked and are retreated using conventional technique and sealing is performed with gutta-percha cones and Grossman cement.

The tooth was then reconstructed with a crown and metal posts by the prosthodontist. A recent control by RVG (*Fig. 7, 8*) shows a positive response with the tooth displaying absence of symptoms.

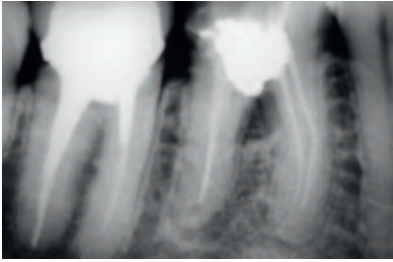


Fig. 1

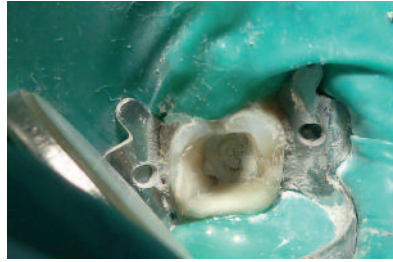


Fig. 2

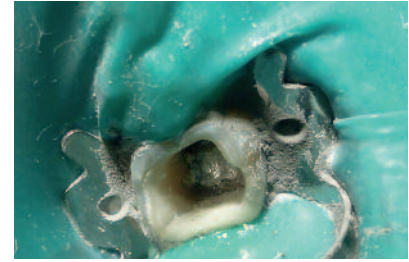

Fig. 2

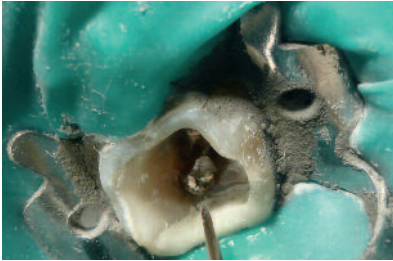

Fig. 4

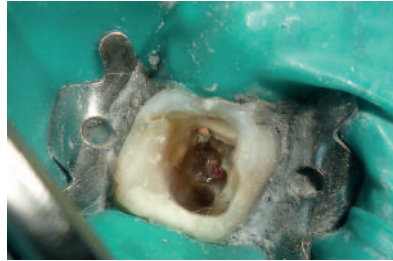


Fig. 5

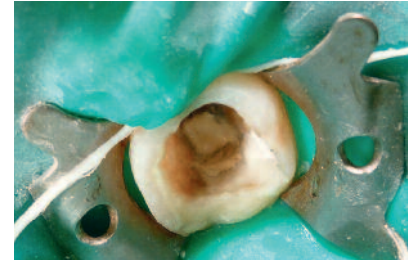

Fig. 6

Conclusions

Perforations in the root canals wall and in the pulp chamber floor are usually one of the most difficult accidents to solve and with an uncertain prognosis. Biodentine™ (Septodont) appears to be a good material with high sealing properties, which is easy to handle, particularly in areas difficult to access. Its color, consistency and hardness mean that the product may be used in places where aesthetics are important, in which it is not easy to pack other products with similar characteristics and at sites where the excess needs removal by milling. The hardening time is another major advantage and work can be continued in the same operating session without affecting the product.

pack other products with similar characteristics and at sites where the excess needs removal by milling.

Additional studies will be necessary in order to check long-term results; for the time being, the treated cases have yielded satisfactory results after 2 and 3 years follow-up X-ray and clinical controls.




Fig. 7

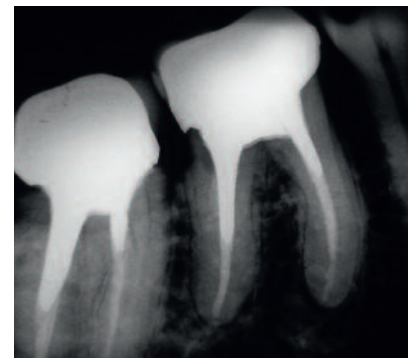

Fig. 8

Author: Prof. Dr. Irene Lorenzo

Co-lecturer of the course for Specialist Training in Endodontics, Graduate School, University of the Republic of Uruguay.

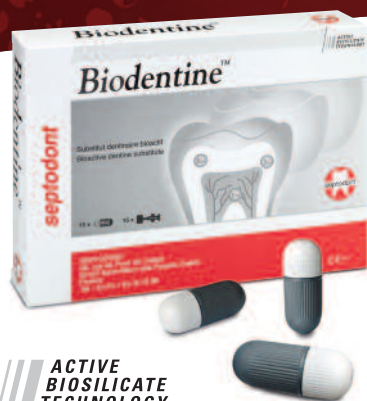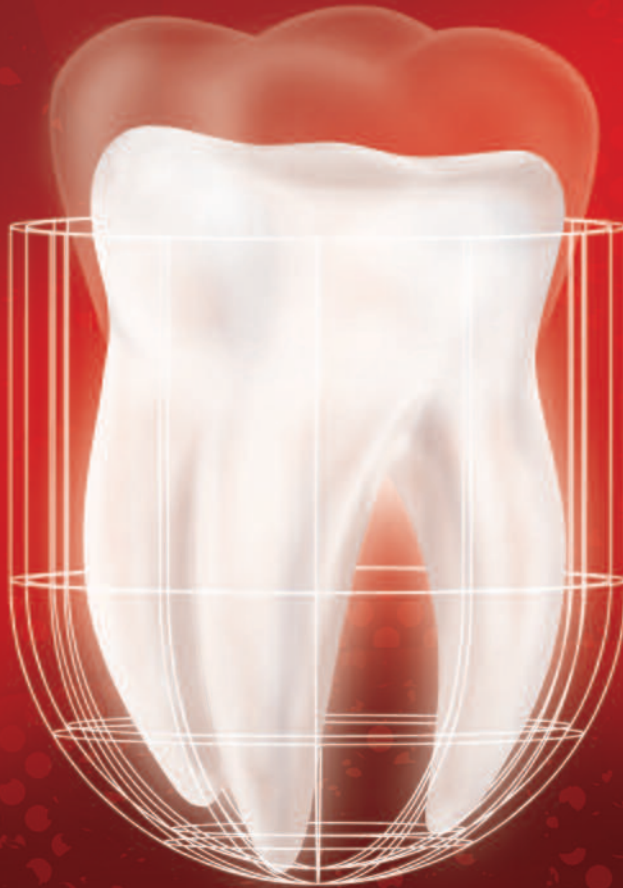Director of the course in Endodontics for Further Education, Graduate School, University of the Republic of Uruguay.

Address: H. Gutierrez Ruiz 1231 Tel. 2908 2666 - Montevideo - Uruguay

Email: irelor@gmail.com

Biodentine™

The first and only dentin in a capsule



ACTIVE
BIOSILICATE
TECHNOLOGY

As the **first all-in-one** biocompatible and bioactive **dentin substitute**, Biodentine™ fully replaces dentin wherever it's damaged.

Biodentine™ helps the remineralization of dentin, preserves the pulp vitality and promotes pulp healing. It replaces dentin with similar biological and mechanical properties.

Improving on **Biodentine™** clinical implementation, you can now bond the composite onto Biodentine™ in the same visit and perform the **full restoration in a single session**.

To enjoy the clinical benefits of the first and only dentin in a capsule, ask your dental distributor for Biodentine™.



Learn more with
the Biodentine™ brochure





The Dental Pharmaceutical Company

INNOVATIVE, SAFE AND EFFECTIVE SOLUTIONS FOR DENTISTRY WORLDWIDE